

Anti-inflammatory effect of *Heliotropium indicum* Linn on lipopolysaccharide-induced uveitis in New Zealand white rabbits

Samuel Kyei^{1,2}, George Asumeng Koffuor^{1,3}, Paul Ramkissoon¹, Elvis Ofori Ameyaw⁴, Emmanuel Akomanin Asiamah⁵

¹Discipline of Optometry, School of Health Sciences, College of Health Sciences, University of KwaZulu-Natal, Private Bag X54001, Durban 4000, South Africa

²Department of Optometry, School of Allied Health Sciences, University of Cape Coast, PMB, Cape Coast, Ghana

³Department of Pharmacology, Faculty of Pharmacy and Pharmaceutical Sciences, College of Health Sciences, Kwame Nkrumah University of Science and Technology, PMB, Kumasi, Ghana

⁴Department of Biomedical and Forensic Sciences, School of Allied Health Science, University of Cape Coast, PMB, Cape Coast, Ghana

⁵Department of Pathology, Komfo Anokye Teaching Hospital, P. O Box 1934, Kumasi, Ghana

Correspondence to: Samuel Kyei. Department of Optometry, School of Allied Health Sciences, University of Cape Coast, PMB, Cape Coast, Ghana. skyei@ucc.edu.gh

Received: 2015-11-05 Accepted: 2016-02-14

Abstract

• **AIM:** To investigate the anti-inflammatory effect of an aqueous whole plant extract of *Heliotropium indicum* (HIE) on endotoxin-induced uveitis in New Zealand white rabbits.

• **METHODS:** Clinical signs of uveitis including flares, iris hyperemia and miosis, were sought for and scored in 1.0 mg/kg lipopolysaccharide (LPS) -induced uveitic rabbits treated orally with HIE (30–300 mg/kg), prednisolone (30 mg/kg), or normal saline (10 mL/kg). The number of polymorphonuclear neutrophils infiltrating, the protein concentration, as well as levels of tumor necrosis factor- α (TNF- α), prostaglandin E₂ (PGE₂), and monocyte chemoattractant protein-1 (MCP-1) in the aqueous humor after the various treatments were also determined. A histopathological study of the anterior uveal was performed.

• **RESULTS:** The extract and prednisolone -treatment significantly reduced ($P \leq 0.001$) both the clinical scores of inflammation (1.0–1.8 compared to 4.40 \pm 0.40 in the normal saline -treated rabbits) and inflammatory cells infiltration. The level of protein, and the concentrations

of TNF- α , PGE₂ and MCP-1 in the aqueous humor were also significantly reduced ($P \leq 0.001$). Histopathological studies showed normal uveal morphology in the HIE and prednisolone-treated rabbits while normal saline-treated rabbits showed marked infiltration of inflammatory cells.

• **CONCLUSION:** The HIE exhibits anti-inflammatory effect on LPS-induced uveitis possibly by reducing the production of pro-inflammatory mediators.

• **KEYWORDS:** monocyte chemotactic protein-1; prostaglandin E₂; tumor necrosis factor- α ; polymorphonuclear neutrophil; iris hyperemia; prednisolone; heliotropium; uveitis

DOI:10.18240/ijo.2016.04.08

Kyei S, Koffuor GA, Ramkissoon P, Ameyaw EO, Asiamah EA. Anti-inflammatory effect of *Heliotropium indicum* Linn on lipopolysaccharide-induced uveitis in New Zealand white rabbits. *Int J Ophthalmol* 2016;9(4):528–535

INTRODUCTION

There are several unverified traditional health care practices in Ghana and elsewhere in Africa. One of such is the traditional use of *Heliotropium indicum* (*H. indicum*) in the treatment of several ailments of the eye. Fluids from the leaves of this plant are squeezed directly into the eye; but whole plant is taken orally as dietary ingredient, in managing local ocular inflammations and postpartum inflammatory reaction respectively. The popularity of *H. indicum* in traditional medicines across the globe has led to several scientific investigations into its pharmacological activity, some of which has resulted in the isolation of some alkaloids of pharmacological importance. Notable among these alkaloids are indicine, indicine-N-oxide, acetyl-indicine, indicinine, heleurine, heliotrine, supinine, supinidine and lindelofidine^[1-6]. One of these bioactive compounds, indicine-N-oxide, is well known for its anti-cancer property. Notwithstanding the growing interest of the scientific community in bio-prospecting for potential pharmaceuticals in *H. indicum* in managing various systems disorders, its traditional use as an antidote to ocular disorders such as uveitis remains largely unconfirmed^[7-8]. This study therefore sought to evaluate the observed traditional use of *H. indicum*

in the management of ocular inflammatory disorders [7,9] in rabbits as an initial step to validate its potential usefulness as an anti-inflammatory agent. It is worthy to note that previous preclinical studies have indicated its anti-inflammatory effect in generalized inflammation however, its intraocular anti-inflammatory effect is yet to be established [10]. A number of animal models have been developed for in depth preclinical studies useful in guiding the development of novel therapeutic approaches to combat the menace of anterior uveitis, a potentially blinding eye disorder [11]. Popular among these models regarding anterior uveitis is endotoxin-induced uveitis [12-13]. This model seems ideal as it typifies intraocular inflammation in humans *i.e.* the exudation of flares, inflammatory cells and preponderance of inflammatory mediators leading to pain, photophobia and reduction in visual acuity [14]. These pathophysiological changes lead to symptoms worrisome enough to victims of uveitis causing them to seek desperate measures such as self medicating with unapproved herbals. Even though there is a low prevalence of uveitis group of disease worldwide (estimated at 0.73%) and accounts for only 0.8% outpatients visits [15-16], it affects people in their prime (averagely 30.7y). This makes it economically important due to its far reaching consequence on productivity and the individual sufferer's autonomy. Improperly managed anterior uveitis could lead to complications such as cataract, secondary glaucoma and macular edema [17]. However, conventional pharmacological management with steroid (the mainstay treatment) is bedeviled with a lot adverse effects equaling the complications of the disease entity [18-19]. Adjunctive therapy such as cycloplegics and mydratics are also not without adverse concerns such as induction of acute angle closure glaucoma and chemotactic neutrophil response despite their useful role in stabilization and restoration of the integrity of the blood-aqueous barrier [20-21]. There is therefore no doubt that alternatives and other unverified traditional practices with botanicals need to be explored to broaden treatment horizon for uveitis. Unlike the previous studies, this study aimed at evaluating the anti-inflammatory effect of aqueous extract of *H. indicum* (HIE) in endotoxin-induced uveitis, a specific intraocular inflammatory model and to predict its possible mechanism of action.

MATERIALS AND METHODS

Plant Collection *H. indicum* was collected in November 2012, from the University of Cape Coast botanical gardens (5.1036° N, 1.2825° W), Cape Coast, Ghana. The plant was identified and authenticated by a botanist at the School of Biological Sciences, College Agricultural and Natural Sciences, University of Cape Coast, Cape Coast, Ghana, where a voucher specimen (Specimen number: 4873) has been deposited.

Preparation of the *Heliotropium Indicum* Aqueous Extract Whole plants of *H. indicum* were washed

thoroughly with tap water and shade-dried. The dry plants were milled into coarse powder by a hammer mill (Schutte Buffalo, New York, NY, USA). One kilogram of the plant powder was mixed with one liter of water. The mixture was Soxhlet extracted at 80 °C, for 24h. The aqueous extract was freeze-dried (Hull freeze-dryer/lyophilizer 140 SQ, Warminster, PA, USA). The powder obtained (yield 12.2%), was labeled HIE, and stored at a temperature of 4 °C. This was reconstituted in normal saline to the desired concentration for dosing in this study.

Experimental Animals and Husbandry Ten-week-old New Zealand rabbits of either sex, weighing 1±0.2 kg were kept in the Animal House of the School of Biological Sciences, University of Cape Coast, Ghana, for use in this study. The animals were housed singly in aluminum cages (34×47×18 -cm³) with soft wood shavings as bedding, under ambient laboratory conditions (temperature 28°C ±2 °C, relative humidity 60%-70%, and a normal light-dark cycle). They were fed with normal commercial pellet diet (Agricare Ltd., Kumasi, Ghana) and had access to water *ad libitum*.

Ethical and Biosafety Considerations The study protocols were approved by the Institutional Review Board on Animal Experimentation, Faculty of Pharmacy and Pharmaceutical Sciences, Kwame Nkrumah University of Science and Technology, Kumasi, Ghana (Ethical clearance number: FPPS/PCOL/0030/2013). All activities performed during the studies conformed to accepted principles for laboratory animal use and care (EU directive of 1986: 86/609/EEC), and Association for Research in Vision and Ophthalmology Statement for Use of Animals in Ophthalmic and Vision Research. Biosafety guidelines for protection of personnel in the laboratory were observed.

Preliminary Phytochemical Screening Using standard procedures, described by Harborne [22] and Kujur *et al* [23], preliminary phytochemical screening was performed on HIE.

Drugs and Chemicals Used Lipopolysaccharide (LPS) (Calbiochem, EMD Chemicals, San Diego, CA, USA) an endotoxin from *Escherichia coli* was used to induce uveitis. Bicinchoninic acid (BCA) protein assay reagent kit (Pierce, Rockford, IL, USA) was used to determine total protein in the aqueous humour. Prednisolone (M&G Pharmaceuticals Ltd., Accra, Ghana) was the reference anti-inflammatory agent in this study. Tumor necrosis factor alpha (TNF-α) ELISA kit (Genorise Scientific, Inc, USA), prostaglandin E₂ (PGE₂) ELISA kit (Wuhan Huamei Biotech Co., Ltd., Wuhan, China), monocyte chemotactic protein 1 (MCP-1) (Biotang Inc., USA) were used in assaying for marker of intraocular inflammation. Chloroform was used to euthanize the animals and normal saline solution (Claris lifesciences limited, Chacharwadi, India) was the vehicle in which other drugs were dissolved.

Induction of Anterior Uveitis All rabbits were examined

for clinical signs of inflammation prior to the induction of ocular inflammation to rule out any pre-existing inflammatory disorder. To induce uveitis, rabbits were injected with 1.0 mg/kg LPS through the marginal ear vein^[24]. Two hours later, the anterior segment of the eye was evaluated by the diffuse and conical beam illumination technique using a slit lamp. Observation of infiltration of cells, flares, iris hyperemia, and miosis was indicative of uveitis.

Effect of *Heliotropium Indicum* Aqueous Extract on Lipopolysaccharide-induced Uveitis LPS-induced uveitic rabbits were grouped into five ($n=5$), labelled I-V, and treated as follows: Groups I, II, and III were treated with 30, 100 or 300 mg/kg HIE respectively (selection of doses was based on reports from previous studies^[25]). Groups IV and V were treated with 30 mg/kg prednisolone and 10 mL/kg normal saline respectively. All treatments were administered orally by means of an oral gavage and dosing was done once daily. Eighteen hours post-LPS injection, both eyes of the rabbits were examined again for vasodilation, and exudation of cells and proteins (clinical signs of uveitis) using the slit lamp (Lombart Instrument Company, Norfolk, VA, USA). The extent of uveitis per treatment groups was given clinical scores. The animals were euthanized and the aqueous humor from the anterior chamber of both eyes collected into sterile Eppendorf tubes using a 25 gauge needle. The aqueous humour was assessed for polymorphonuclear neutrophils (PMNs), total proteins, MCP-1, PGE₂, TNF- α .

Clinical Score of Uveitis The scoring was performed as follows: iris hyperemia/redness (0-2), flare (0-1), cells in the anterior chamber (0-2), hypopyon/pus in the anterior chamber (0-1), miosis (0-1). The maximum practicable score was 7^[26].

Polymorphonuclear Neutrophil Count Small quantities of a 1:10 dilution (Diluent: Türk's stain solution) of the aqueous humour collected was from the various treatment groups were pipetted onto the counting chamber of the Improved Neubauer Haemocytometer (Depth 0.1 mm, Area: 1/400 mm²; Yancheng Cordial Lab Glassware Co. Ltd., Jiangsu Province, China). PMNs were counted from four "large" squares (volume: 0.4 mm³) using a Ceti magnum-T/trinocular microscope for fluorescence (Medline Scientific limited, UK), under objective magnification of 40 \times . The number of PMNs was determined per mm³ of aqueous humour (taking into account the dilution dynamics).

Determination of Total Protein Concentration A Bicinchoninic Acid (BCA) protein assay kit (Pierce, Rockford, IL, USA) was used to determine the total protein concentration in the aqueous humour. Fifty microliter (50 μ L) quantities of aqueous humour collected from the various treatment groups as well as standard bovine serum albumin (BSA) were introduced into well on a 96-well microplate

with a micropipette. A 200 μ L quantity of working reagent, constituted according to the manufacturer's instructions, was mixed thoroughly with the content of each well and shaken for 30s. The microplate and its content was then incubated at 37 $^{\circ}$ C for 30min and allowed to cool to room temperature. Absorbances of the mixtures were measured at 562 nm using an URIT-660 microplate reader (URIT Medical Electronic Co., Ltd, Guangxi, China). Each determination was done in triplicate.

Determination of Monocyte Chemotactic Protein 1 Concentration The concentration of MCP-1 in the aqueous humour of each sample from the treatment groups was determined using a double-antibody sandwich ELISA kit per manufacturer's the procedure. All samples were assayed in duplicate and on the same plate. The detection limits for this assay was 15-4000 pg/mL. In brief, the samples were loaded along with the standards, and the biotinylated-MCP-1 antibody was then added. The wells were washed to remove unbound antibody-enzyme reagent, after which tetramethylbenzidine (TMB) substrate was added. The addition of the TMB substrate produced blue coloration upon catalysis by horseradish peroxidase (HRP) enzyme. The reaction was terminated by adding the acidic stop solution which changed the solution from blue to yellow. Absorbances of the mixtures were measured at 450 nm using an URIT-660 microplate reader (URIT Medical Electronic Co., Ltd., Guangxi, China). The concentration of MCP-1 was calculated using a standard curve. Each determination was done in triplicate.

Determination of Prostaglandin E₂ Levels The ELISA kit had a minimum detectable dose of rabbit PGE₂ of less than 7.8 pg/mL. The standards or samples were prepared according to the manufacturer's instruction which were pipette into the microtiter plate wells with a biotin-conjugated polyclonal antibody preparation specific for rabbit PGE₂. Subsequently, avidin conjugated to HRP was introduced into each well and incubated. Following this, TMB (3,3',5,5' tetramethyl-benzidine) substrate solution was added to each well. Only wells which contain PGE₂, biotin-conjugated antibody and enzyme-conjugated avidin showed a change in color. The enzyme-substrate reaction was stopped by the adding 50 μ L of sulphuric acid solution. After which the color intensity was measured spectrophotometrically at a wavelength of 450 nm. The concentration of PGE₂ in the samples was then determined by comparing the optical densities of the samples to the standard curve. Each determination was done in triplicate.

Determination of Tumor Necrosis Factor Alpha Levels in Aqueous Humour A commercial ELISA kit for the estimation of TNF- α in the rabbit aqueous humour (detection range: 31-2000 pg/mL; sensitivity: 0.8 pg/mL) was used. It employs a quantitative sandwich enzyme immunoassay

technique with improved performance owing to its biotin-streptavidine chemistry. Standards and samples (100 μ L) were pipetted into a pre-coated microplate with antibody specific for rabbit TNF- α in which any TNF- α present was bound by the immobilized antibody. After washing away the unbound antibody substances, a detection antibody specific for rabbit TNF- α was added to the wells. A detection reagent was then added which led to color development in proportion to the amount of TNF- α bound in the initial step. The color development was stopped and the intensity of the color was measured at 540 nm using an URIT-660 microplate reader (URIT Medical Electronic Co., Ltd., Guangxi, China). All determinations were in triplicate.

Histopathological Assessment The enucleated eyes of animals from the treatment groups were fixed in 4% phosphate-buffered paraformaldehyde, and embedded in paraffin. Sections of the anterior uvea of the treated (HIE, prednisolone or normal saline) rabbit were made and stained with hematoxylin and eosin [26] and fixed on glass slides for microscopic examination at the Pathology Department of the Komfo Anokye Teaching Hospital, Kumasi, Ghana for histopathological assessment by a specialist pathologist.

Statistic Analysis Data obtained for control, test, and reference drug effects were analyzed by one-way analysis of variance followed by Dunnett's multiple comparisons test using GraphPad Prism (version 5.03; GraphPad, La Jolla, CA, USA). Values were expressed as the mean \pm standard error of the mean. $P \leq 0.05$ was considered to be statistically significant.

RESULTS

Phytochemical Screening Preliminary phytochemistry showed that flavonoids, saponins, cyanogenic glycosides, sterol, tannins and alkaloids were present in HIE (Table 1).

Effect of *Heliotropium Indicum* Aqueous Extract on Lipopolysaccharide -induced Uveitis There was remarkable infiltration of cells and flares (protein exudates) in the aqueous humour, as well as intense iris hyperemia and vasodilation (clinical score: 4.40 ± 0.40) of uveitic rabbits treated with normal saline. However, HIE- and prednisolone-treated groups showed no infiltration, or significantly reduced ($P \leq 0.001$) infiltration of cells and flares, iris hyperemia and vasodilation; reducing clinical scores to between 1.0 to 1.8 (Figure 1).

Polymorphonuclear Neutrophil Count and Total Protein Concentration There was significant ($P \leq 0.001$) reduction of PMNs and protein exudation into the aqueous humour of the HIE and prednisolone-treated animals compared to the normal saline-treated group (Figure 2A, 2B).

Monocyte Chemotactic Protein 1, Prostaglandin E₂, Tumor Necrosis Factor Alpha Levels in Aqueous Humour Treatment with HIE or prednisolone caused anti-inflammation as it significantly ($P \leq 0.001$) reduced the

Table 1 Results obtained after preliminary phytochemical screening of HIE

Phytochemical tested for	Results obtained
Anthraquinones	-
Tannins	+
Flavonoids	+
Alkaloids	+
Sterols	+
Glycosides	+
Saponins	+
Triterpenoids	-

+: Present; -: Absent.

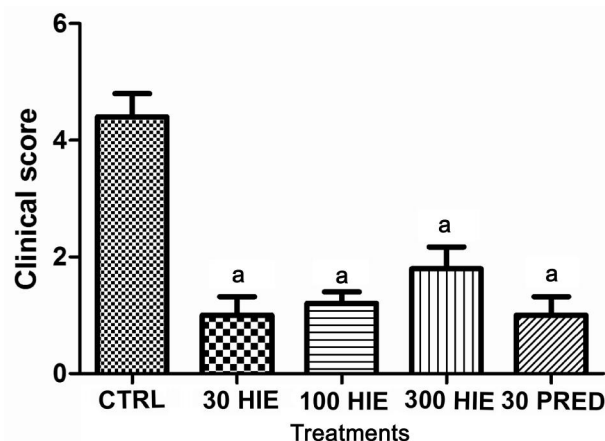


Figure 1 The clinical score of inflammation in LPS-induced uveitic rabbits treated with 30, 100 and 300 mg/kg HIE, 30 mg/kg prednisolone (PRED), and 10 mL/kg normal saline (CTRL) ^a $P \leq 0.001$ ($n=5$), ANOVA followed by Dunnett's *post hoc* test.

levels of MCP-1, PGE₂, TNF- α , in the aqueous humour nevertheless the normal saline-treated rabbits had higher concentrations of these chemokine and cytokines in their aqueous humour (Figures 3, 4 and 5).

Histopathological Assessment The histopathological assessment did not reveal any signs of inflammation in anterior uvea in rabbits treated with HIE or prednisolone. However, there were histopathological signs of inflammation characterized by neutrophil infiltration into the uveal tissues in the normal saline treated rabbits (Figure 6).

DISCUSSION

In this study, the anti-inflammatory property of an aqueous whole plant HIE was studied in lipopolysaccharide-induced uveitis in rabbits. The lipid A portion of LPS, a component of a gram negative bacterial cell wall, is responsible for the explicit uveitogenic tendency in rodents [27]. Injection of LPS results in the breakdown of the blood-aqueous barrier *via* a series of mechanisms beginning with the activity of the systemically injected LPS on local macrophages which in turn provoke the production of pro-inflammatory cytokines such as TNF- α and interleukin-1 [28]. Chemokines such as MCP-1/CCL2 are released in response to signals from these pro-inflammatory cytokines where they regulate trafficking

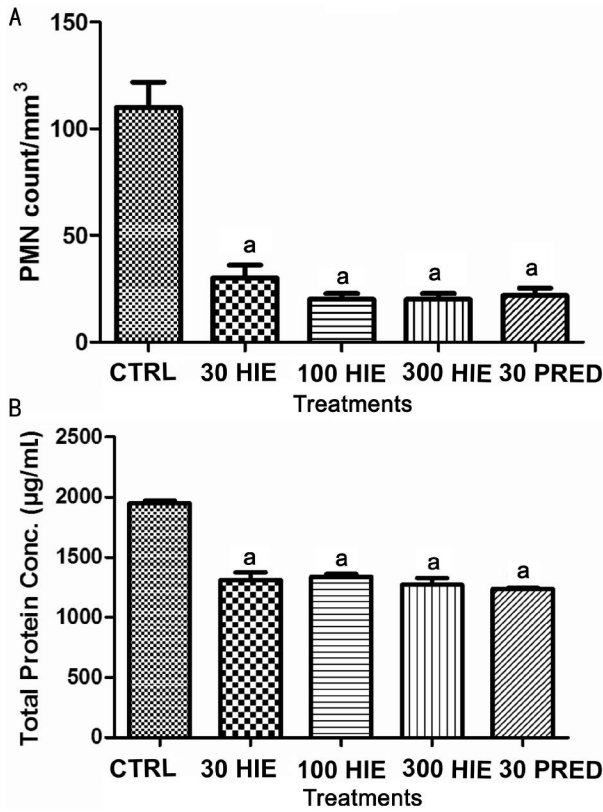


Figure 2 The effect of 30, 100 and 300 mg/kg HIE, 30 mg/kg prednisolone (PRED), and 10 mL/kg normal saline (CTRL) on: (A) PMN count, (B) total protein concentration in the aqueous humour of the eyes of LPS-induced uveitis rabbits ^a $P \leq 0.001$ ($n=5$), ANOVA followed by Dunnet's *post hoc* test.

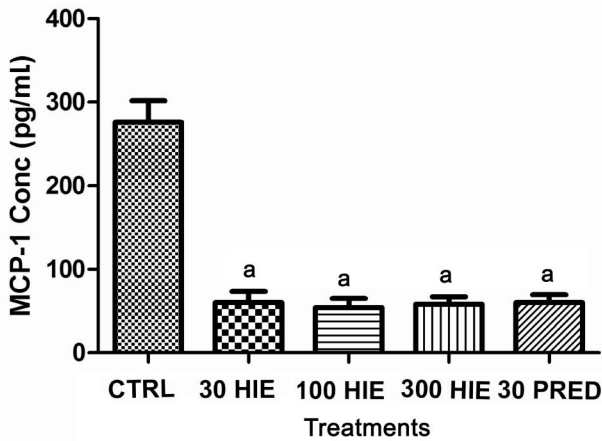


Figure 3 The effect of 30, 100 and 300 mg/kg HIE, 30 mg/kg prednisolone (PRED), and 10 mL/kg normal saline (CTRL) on MCP-1 in the aqueous humour of LPS-induced uveitis rabbits ^a $P \leq 0.001$ ($n=5$), ANOVA followed by Dunnet's *post hoc* test.

of inflammatory cells such as monocytes and neutrophils into the anterior uvea [29]. Under the auspices cytokines, macrophages and neutrophils secrete prostaglandin E₂ and nitric oxide, which actually causes the breakdown of the blood-aqueous barrier leading to the observable infiltration of cells and flare (protein exudation) in the anterior chamber during the clinical stage of the disease process [11,30]. The noticeable miosis especially in rabbit with uveitis can be

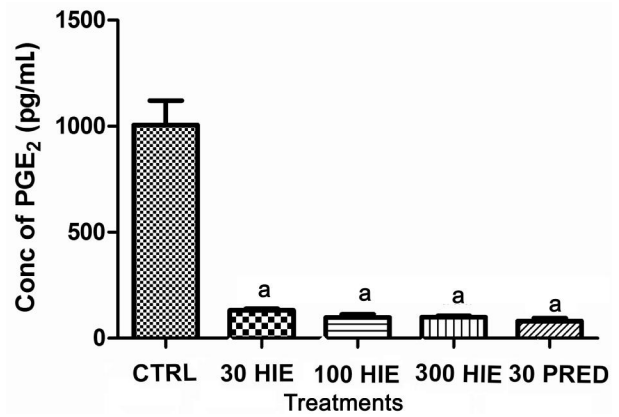


Figure 4 The effect of 30, 100 and 300 mg/kg HIE, 30 mg/kg prednisolone (PRED), and 10 mL/kg normal saline (CTRL) on PGE₂ in the aqueous humour of LPS-induced uveitis rabbits ^a $P \leq 0.001$ ($n=5$), ANOVA followed by Dunnet's *post hoc* test.

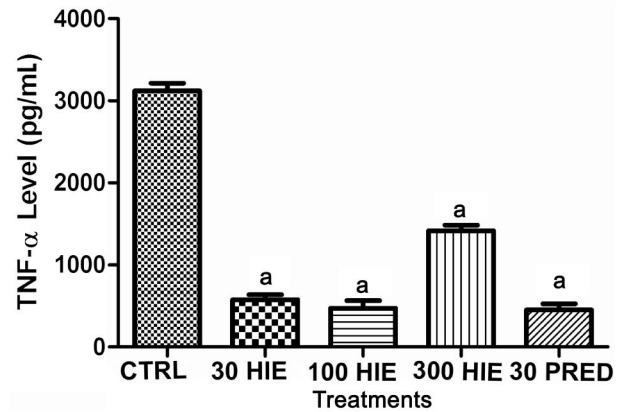


Figure 5 The effect of 30, 100 and 300 mg/kg HIE, 30 mg/kg prednisolone (PRED), and 10 mL/kg normal saline (CTRL) on TNF-α level in the aqueous humour of LPS-induced uveitis rabbits ^a $P \leq 0.001$ ($n=5$), ANOVA followed by Dunnet's *post hoc* test.

explained by the release substance P from the peripheral nerve endings in reaction to deleterious stimuli^[31].

Results from this study indicate that the aqueous whole plant HIE has potent anti-inflammatory effect in endotoxin-induced uveitis which gives credence to its traditional use in managing inflammatory eye disorders^[7,9]. TNF-α is one of the earliest cytokine involved in the pathogenesis of LPS-induced uveitis. Other researchers have reported that symptoms of Behcet's disease uveitis could be relieved by anti-TNF-α antibody treatment [32]. It is an established fact that the transcription of TNF-α is under the influence of nuclear factor-kappa B (NF-κB) and a positive loop exist between amplification of cytokine cascade during inflammation (*i.e.* TNF-α) and activation of NF-κB [33-34]. In this study HIE presumably down-regulated TNF-α in the aqueous humor, by obstructing the generation of the positive loop between TNF-α and NF-κB.

MCP-1 which is also transcriptionally controlled by NF-κB and protease activated receptor 1 (PAR1) signaling^[35]. It has been found be an important inflammatory marker both in

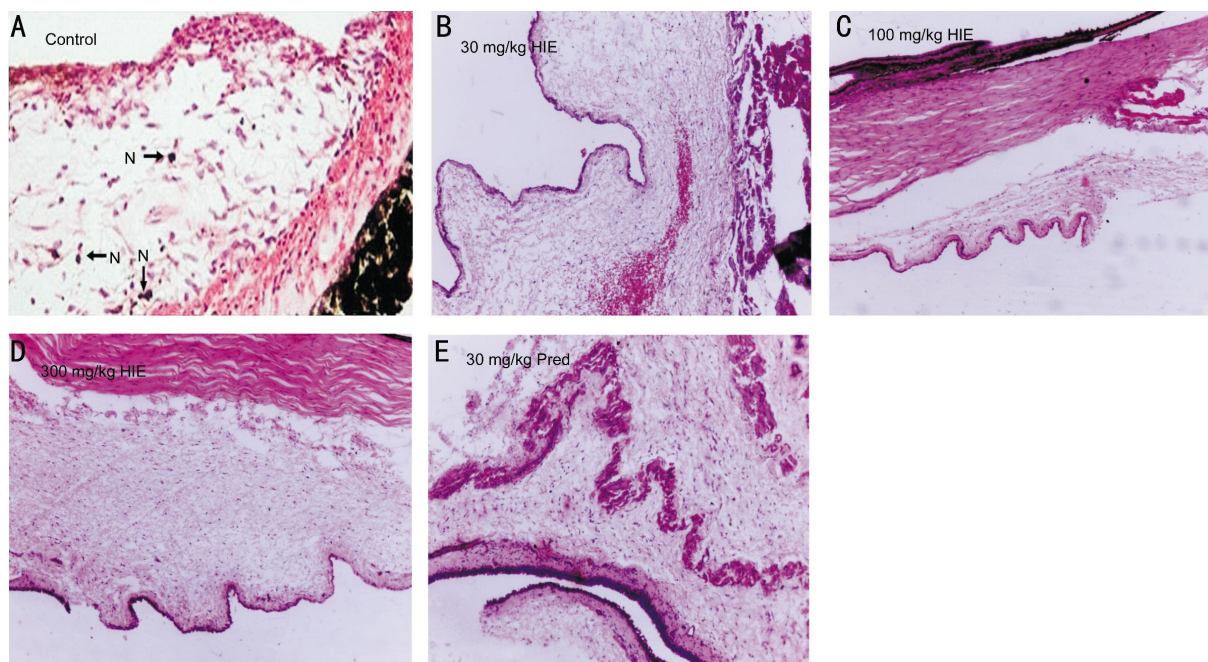


Figure 6 Photomicrographs of anterior uvea A: Marked infiltration of neutrophils in iris tissue of 10 mL/kg normal saline treatment (Control) rabbit; B: 30 mg/kg HIE treated rabbit with normal histology of anterior uvea and well defined margins; C: 100 mg/kg HIE treated rabbit with normal histology of the anterior chamber angle and uveal; D: 300 mg/kg HIE treated with normal histology of the anterior uvea and no inflammatory cells. N: Neutrophils. E: 30 mg/kg prednisolone treated with normal architecture of the anterior uveal tissue.

human and animal models of uveitis [30]. The low concentration of MCP-1, in the aqueous humour of the extract treated rabbits compared to the normal saline treated (control) further elucidate the therapeutic importance of the extract in obstructing classical NF- κ B pro-inflammatory and protease activated receptor 1 (PAR1) signaling mechanism [35-36]. This is also supported by the normal histology of the anterior uveal tissue which was compromised in the control group.

PGE₂, a major player in the causation of blood-aqueous barrier breakdown [11], leading to protein exudation into the anterior chamber, was found to be reduced. This significantly prevented protein exudation into the aqueous humour of the extract-treated rabbits, which was comparable to the prednisolone-treated rabbits. The expression of the inducible enzyme, involved in the synthesis of COX-2, is also elicited by NF- κ B signaling or TAK1-IKK-NF- κ B signaling pathway [37]. Again, cAMP signalling pathway co-operates with LPS in the induction of COX-2 and mPGES-1 transcriptional activation [38]. The findings suggest that the attenuated ocular inflammation can be ascribed in part to the down-regulation of these mediators by HIE.

Reactive oxygen species (ROS) are considered second messengers in NF- κ B activation and cytokine expression [39-40]. A probable mechanism of inhibiting NF- κ B activation and inflammatory cascade propagation by HIE is the scavenging of ROS. Several chemo-preventive phytoconstituents such as alkaloids, flavonoids and sterols in natural products [41-42], have been shown to inhibit COX-2 and iNOS expression by blocking improper NF- κ B activation. There is convincing

evidence that indicate extracellular-regulated protein kinase and p38 mitogen-activated protein kinase are important factors of the intracellular signaling cascades accountable for NF- κ B activation in reaction to a number of external stimuli [43]. Prednisolone on the other hand, like all other corticosteroids are potent inhibitors of inflammatory processes and are widely used in the treatment of uveitis and other inflammatory disorders. It exerts its effect by directly binding of the glucocorticoid/glucocorticoid receptor complex to glucocorticoid receptive essentials in the promoter region of genes, or by an interaction of this complex with other transcription factors, more so activating protein-1 or NF- κ B. It inhibits several inflammation-associated molecules such as cytokines, chemokines, arachidonic acid metabolites, and adhesion molecules [44].

By inhibiting multiple pro-inflammatory cytokines, the aqueous whole plant HIE exerts potent anti-inflammatory effect on LPS-induced uveitis in New Zealand white rabbits. This therefore provides scientific support for the traditional use as an ocular anti-inflammatory agent.

ACKNOWLEDGEMENTS

The authors are grateful to the management and staff of Life Science Diagnostic Centre, Cape Coast for permitting us to use their facility for aspects of the this study. We are also thankful to Ms. Carrin Martins for proof reading this manuscript.

Author Kyei S conceived the idea, designed the study, wrote the protocol, managed the literature searches, data collection and wrote the first draft of the manuscript. Asumeng Koffuor

G and Ramkissoon P were involved in the conception and design of the study, managed the analyses of the study. Ofori Ameyaw E was involved in the design of the study, managed literature search and critically revised the content. Akomanin Asiamah E performed the histological evaluations, interpretation of data. All authors read and approved the final manuscript.

This article results from research towards a PhD (Optometry) degree in the Discipline of Optometry at the University of KwaZulu Natal under the supervision of Dr. George A. Koffuor and co-supervision of Prof. Paul Ramkissoon.

Foundation: Partly supported by University of Cape Coast.

Conflicts of Interest: Kyei S, None; Koffuor GA, None; Ramkissoon P, None; Ameyaw EO, None; Asiamah EA, None.

REFERENCES

- 1 Kone WM, Kande B. Qualitative analysis of the pyrrolidine alkaloids from 11 Asteraceae and Boraginaceae used in traditional medicine in Cote d'Ivoire. *Research J of Phytochemistry* 2012;6(3):75–83.
- 2 Sharma RA, Singh B, Singh D, Chandrawat P. Ethnomedicinal, pharmacological properties and chemistry of some medicinal plants of Boraginaceae in India. *J Med Plant Res* 2009;3(13):1153–1175.
- 3 Rahman MA, Mia MA, Shahid IZ. Pharmacological and phytochemical screen activities of roots of *Heliotropium indicum*. *Pharmacologyonline* 2011;1:185–192.
- 4 Dash GK, Abdullah MS. A review on *Heliotropium Indicum* L. (Boraginaceae). *International Journal of Pharmaceutical Sciences and Research* 2013;4(4), 1253–1258.
- 5 El-Shazly A, Wink M. Diversity of pyrrolizidine alkaloids in the Boraginaceae structures, distribution, and biological properties. *Diversity* 2014;6(2):188–282.
- 6 Costa RS, Camelo SRP, Ribeiro-Costa RM, Barbosa WLR, Vasconcelos F, Silva Junior JOC. Physical, chemical and physico-chemical control of *Heliotropium indicum* Linn, Boraginaceae powder and tincture. *International Journal of Pharmaceutical Sciences and Research* 2011;2(7): 2211–2216.
- 7 Rahmatullah M, Das AK, Ariful Md. AH, Mollik H, Jahan R, Khan M. An ethnomedicinal survey of Dhamrai sub-district in Dhaka District, Bangladesh. *Eurasian J Sustain Agric* 2009;3(3):881–888.
- 8 Mollik AH, Hossain S, Paul AK, Rahman TU, Jahan R, Rahmatullah M. A comparative analysis of medicinal plants used by folk medicinal healers in three districts of Bangladesh and inquiry as to mode of selection of medicinal plants. *Ethnobotany Research and Applications* 2010;8:195–218.
- 9 Roeder E, Wiedenfeld H. Plants containing pyrrolizidine alkaloids used in the traditional Indian medicine—including ayurveda. *Pharmazie* 2013;68 (3):83–92.
- 10 Srinivas K, Rao MEB, Rao SS. Anti-inflammatory activity of *Heliotropium indicum* Linn and *Leucas aspera spreng* in albino rats. *Ind J Pharmacol* 2000;32(1):37–38.
- 11 Bansal S, Barathi VA, Iwata D, Agrawal R. Experimental autoimmune uveitis and other animal models of uveitis: an update. *Indian J Ophthalmol* 2015;63(3):211–218.
- 12 Rosenbaum JT, McDevitt HO, Guss RB, Egbert PR. Endotoxin-induced uveitis in rats as a model for human disease. *Nature* 1980;286 (5773): 611–613.
- 13 Kogiso M, Tanouchi Y, Mimura Y, Nagasawa H, Himeno K. Endotoxin-induced uveitis in mice. 1. Induction of uveitis and role of T lymphocytes. *Jpn J Ophthalmol* 1992;36(3):281–290.
- 14 Camilo EN, Moura GL, Arantes TE. Clinical and epidemiological characteristics of patients with uveitis in an emergency eye care center in Brazil. *Arq Bras Oftalmol* 2014;77(1):30–33.
- 15 Dandona L, Dandona R, John RK, McCarty CA, Rao GN. Population based assessment of uveitis in an urban population in southern India. *Br J Ophthalmol* 2000;84(7):706–709.
- 16 London NJ, Rathinam SR, Cunningham ET Jr. The epidemiology of uveitis in developing countries. *Int Ophthalmology Clin* 2010;50(2):1–17.
- 17 Schlaegel TF Jr. Essentials of uveitis. Boston: Little, Brown & Co. 1969.
- 18 James ER. The etiology of steroid cataract. *J Ocul Pharmacol Ther* 2007;23(5):403–420.
- 19 Clark AF, Wordinger RJ. The role of steroids in outflow resistance. *Exp Eye Res* 2009;88(4):752–759.
- 20 Foster CS, Vitale A. Diagnosis and treatment of uveitis. 2nd Ed. Jaypee Highlights Medical Publishers Inc. 2012.
- 21 Agrawal RV, Murthy S, Sangwan V, Biswas J. Current approach in diagnosis and management of anterior uveitis. *Indian J Ophthalmol* 2010; 58(1):11–19.
- 22 Harborne JB. Phytochemical Methods: A Guide to modern techniques of plant analysis. 3rd ed. London, UK: Chapman and Hall, 1998.
- 23 Kujur RS, Singh V, Ram M, Yadava HN, Singh, KK, Kumari S, Roy BK. Antidiabetic activity and phytochemical screening of crude extract of *Stevia rebaudiana* in alloxan-induced diabetic rats. *Pharmacognosy Res* 2010;2 (4):258–263.
- 24 Touchard E, Omri S, Naud MC, Berdugo M, Deloche C, Abadie C, Jonet L, Jeanny JC, Crisanti P, de Kozak Y, Combette JM, Behar-Cohen F. A peptide inhibitor of c-Jun N-terminal kinase for the treatment of endotoxin-induced uveitis. *Invest Ophthalmol Vis Sci* 2010;51 (9): 4683–4693.
- 25 Boye A, Koffuor GA, Amoateng P, Ameyaw EO, Abaitey AK. Analgesic activity and safety assessment of *Heliotropium indicum* Linn. (Boraginaceae) in rodents. *International Journal of Pharmacology* 2012;8: 91–100.
- 26 Iba T, Saitoh D. Efficacy of antithrombin in preclinical and clinical applications for sepsis associated disseminated intravascular coagulation. *J Intensive Care* 2014;2(1):66.
- 27 Allensworth JJ, Planck SR, Rosenbaum JT, Rosenzweig HL. Investigation of the differential potentials of TLR agonists to elicit uveitis in mice. *J Leukoc Biol* 2011;90(6):1159–1166.
- 28 Zarogoulidis P, Yarmus L, Darwiche K, Walter R, Huang H, Li Z, Zaric B, Tsakiridis K, Zarogoulidis K. Interleukin-6 cytokine: a multifunctional glycoprotein for cancer. *Immunome Res* 2013;9(62):16535.
- 29 Kolattukudy PE, Niu J. Inflammation, endoplasmic reticulum stress, autophagy, and the monocyte chemoattractant protein-1/cer2 pathway. *Cir Res* 2012;110(1):174–189.
- 30 Chao SC, Vagaggini T, Nien CW, Huang S-C, Lin HY. Effects of lutein and zeaxanthin on Lps-induced secretion of il-8 by uveal melanocytes and relevant signal pathways. *J Ophthalmology* 2015;2015:152854.
- 31 Nishida T, Inui M, Nomizu M. Peptide therapies for ocular surface disturbances based on fibronectin-integrin interactions. *Prog Ret Eye Res* 2015;47:38–63.
- 32 Chen FT, Liu YC, Yang CM, Yang CH. Anti-inflammatory effect of the proteasome inhibitor bortezomib on endotoxin-induced uveitis in rats. *Invest Ophthalmol Vis Sci* 2012;53(7):3682–3694.

- 33 Reuter S, Gupta SC, Chaturvedi MM, Aggarwal BB. Oxidative stress, inflammation, and cancer: how are they linked? *Free Radic Biol Med* 2010; 49(11):1603–1616.
- 34 DiDonato JA, Mercurio F, Karin M. NF- κ B and the link between inflammation and cancer. *Immunological Rev* 2012;246:379–400.
- 35 Lee H, Hamilton JR. Physiology, pharmacology, and therapeutic potential of protease-activated receptors in vascular disease. *Pharmacol Ther* 2012;134(2):246–259.
- 36 Heiligenhaus A, Thurau S, Hennig M, Grajewski RS, Wildner G. Anti-inflammatory treatment of uveitis with biologicals: new treatment options that reflect pathogenetic knowledge of the disease. *Graefes Arch Clin Exp Ophthalmol* 2010;248(11):1531–1551.
- 37 Zhang J, Lei T, Chen X, Peng Y, Long H, Zhou L, Huang J, Chen Z, Long Q, Yang Z. Resistin up-regulates COX-2 expression via TAK1-IKK-NF- κ B signaling pathway. *Inflammation* 2010;33(1):25–33.
- 38 Díaz-Muñoz MD, Osma-García IC, Fresno M, Iñiguez MA. Involvement of PGE2 and the cAMP signalling pathway in the up-regulation of COX-2 and mPGES-1 expression in LPS-activated macrophages. *Biochem J* 2012; 443(2):451–461.
- 39 Morgan MJ, Liu ZG. Crosstalk of reactive oxygen species and NF- κ B signaling. *Cell Res* 2011;21(1):103–115.
- 40 Izzi V, Masuelli L, Tresoldi I, Sacchetti P, Modesti A, Galvano F, Bei R. The effects of dietary flavonoids on the regulation of redox inflammatory networks. *Front Biosci (Landmark Ed)* 2012;17:2396–2418.
- 41 Jayakumar T, Thomas PA, Geraldine P. In-vitro antioxidant activities of an ethanolic extract of the oyster mushroom, *Pleurotus ostreatus*. *Int Food Sci Emerg Tech* 2009;10(2):228–234.
- 42 Pragada RR, Rao Ethadi S, Yasodhara B, Praneeth Dasari VS, Mallikarjuna Rao T. In-vitro antioxidant and antibacterial activities of different fractions of *Heliotropium indicum* L. *Journal of Pharmacy Research* 2012;5(2):1051–1053.
- 43 Cargnello M, Roux PP. Activation and function of the MAPKs and their substrates, the MAPK-activated protein kinases. *Microbiol Mol Biol Rev* 2011;75(1):50–83.
- 44 Ismael H, Horst M, Farooq M, Jordon J, Patton JH, Rubinfeld IS. Adverse effects of preoperative steroid use on surgical outcomes. *Am J Surg* 2011;201(3):305–308.