

See discussions, stats, and author profiles for this publication at: <https://www.researchgate.net/publication/313678764>

# THE THERAPEUTIC IMPORTANCE OF CASSIA OCCIDENTALIS – AN OVERVIEW

Article · January 2015

---

CITATIONS

68

READS

3,203

1 author:



[Ali Esmail Al-Snafi](#)

University of Thi-Qar - College of Medicine

332 PUBLICATIONS 9,423 CITATIONS

SEE PROFILE

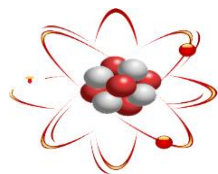
Some of the authors of this publication are also working on these related projects:



Medicinal plants with antiinflammatory, antipyretic and analgesic effects [View project](#)



Medicinal plants with antimicrobial effects [View project](#)



## THE THERAPEUTIC IMPORTANCE OF *CASSIA OCCIDENTALIS*- AN OVERVIEW

Ali Esmail Al-Snafi\*

Department of Pharmacology, College of Medicine, Thi qar University, Nasiriyah, P O Box 42, Iraq.

### ABSTRACT

*Cassia occidentalis* is widely distributed and very commonly used plant. It contained many chemical groups included alkaloids, anthocyanosides, phenolics, proteins, phlobatannins, steroids, tannins, flavonoids, anthroquinone, saponins, terpenes, resins, balsams, amino acids, carbohydrates, sugars and cardiac glycosides. *Cassia occidentalis* exerted many pharmacological effects included antimicrobial, anthelmintic, insecticidal, antioxidant, antianxiety, antidepressant, antimutogenic antidiabetic, wound healing, hepatoprotective, renoprotective, sun protective, smooth muscles relaxation, immune-modulating, antiinflammatory, analgesic, antipyretic and other effects. The present review will highlight the chemical constituents and the pharmacological and therapeutic effects of *Cassia occidentalis*.

**Keywords:** *Cassia occidentalis*, Chemical constituents, Pharmacology.

### INTRODUCTION

For the past decades, there has been an increasing interest in the investigation of the pharmacological effects of different extract obtained from plants as a source of new drugs [1-46]. The phytochemical analysis showed that the different parts of *Cassia occidentalis* contained many chemical groups included alkaloids, anthocyanosides, phenolics, proteins, phlobatannins, steroids, tannins, flavonoids, anthroquinone, saponins, terpenes, resins, balsams, amino acids, carbohydrates, sugars and cardiac glycosides. *Cassia occidentalis* exerted many pharmacological effects included antimicrobial, anthelmintic, insecticidal, antioxidant, antianxiety, antidepressant, antimutogenic antidiabetic, wound healing, hepatoprotective, renoprotective, sun protective, smooth muscles relaxation, immune-modulating, antiinflammatory, analgesic, antipyretic and other effects. The present was designed to highlight the chemical constituents and the pharmacological and therapeutic effects of *Cassia occidentalis*.

**Synonyms:** *Senna occidentalis*.

### Common names:

**Brazil:** Mata Pasta, Fedegoso, Paramarioba;

**Cameroon:** Gin-i-nel; **China:** Wang Jiang Nan, Ye Bian Dou, Li Cha; **English:** Stinking Weed, Negro Coffee, Coffee Senna, Antbush; **France:** Bentamare, Café Bastard, Casse Puante, Café des Niors; **India:** Kassaumdh, Barrikassaumdh (Hindi), Doddaagace (Kannada); Panniviram, Ponnativiram (Malayalam); Kasamardah (Sanakrit); Ponnativirai, Peravirai, Nattam takarai (Tamil); Kasinda (Telugu) **Indonesia:** Menting (Java), Kopi Andelan (Sumatera); **Japan:** Habuso; **Korea:** Soggjolvjong; **Malaysia:** Kacang Kota, Ketepeng Hutan; **Niger:** Sanga-sanga, Raydore; **Nigeria:** Kire, Rere, Rai' dore; **South Africa:** Moshabela moha, Tsinyembane, Umnwanda nyoka **Spain:** Bricho, Brusca, Frijolillo, Guanina; **Thailand:** Chumhet tet, and **Vietnam:** Moug hoe [47-51].

### Taxonomic Classification

**Kingdom:** Plantae, **Phylum:** Spermatophyta, **Subphylum:** Angiospermae, **Class:** Dicotyledonae, **Order:** Fabales, **Family:** Fabaceae, **Subfamily:** Caesalpinioideae, **Genus:** *Cassia*, **Species:** *Cassia occidentalis* [52].

### Distribution

It is native to the tropical and subtropical regions of America. Now, it is widely distributed in Asia, Africa,

North and Central America and Caribbean [53-56].

### Description

**Root:** tap root measures 15-25cm. in length and 1-15 cm. in diameter; at the upper extremity they are cylindrical and tapering, bearing the few lateral branches and many rootlets. Surface is rough due to presence of many transversely running lenticels and a few root scars of fallen roots. It is dark brown in colour externally and creamy internally. Fracture is hard and fibrous. The root possesses characteristic odour and acrid taste. **Stem:** erect, 1-2 meters long, 0.5-1.5 cm. Thickness at its basal region, branching at nodes spirally. Young stem is green in colour and furrowed, while the mature stem is light brown to dark in colour. Branches many, ascending, flexuose, smooth, showing dark purplish green colour on their surface. The internode is 2-4 cm. Long. **Leaves:** Compound, pinnate, 9-13-20cm. Long, petiolate, petiole (rachis) pulvinate, grooved or nearly round, glabrous, 5-12cm. Long, showing dark purplish colour in the grooved portion and greenish on the opposite side. **Leaflets:** 3-5 pairs, opposite, unequal, the lower most smallest and ovate, the superior ones longer, 2.5-8cm. Broad, very short stalk, ovate, oblong to ovate, lanceolate, acute or acuminate, base usually rounded and somewhat oblique, glabrous above and pubescent beneath. The leaves possess a very foetid odour. **Flower:** Yellow with 1 to 2 cm in diameter, inflorescence racemes few -flowered, axillary, and also forming terminal panicle; bracts caduceous. **Fruit:** Flat pods 10-12cm. long with 10-30 seeds. Areolate seeds are pointed at end and blunt at the other [57-58].

### Traditional uses

Leaves were used externally and internally in skin diseases, itches, scabies and ringworm. Hot decoction preferred to quinine for its tonic properties. Paste of leaves and calcium hydroxide applied to abscesses for quick opening and clearing of pus [59-60]. The paste of leaves was externally applied to wounds, sores, itch, cutaneous diseases, bone fracture, fever, ringworm, skin diseases, throat infection and to cure sore eyes. It was also used in hematuria, in rheumatism, for typhoid fever and tuberculosis, asthma, haemoglobin disorders, to cure leprosy and to treat diabetes [61-62]. The leaves/roots were an ingredient of many popular herbal liver tonics and medicines for liver disorders. People use it also for the treatment of insect bites, snakebite, scorpion sting, constipation, oedema, fever, inflammation and rheumatism [63]. Its roots, leaves, flowers and seeds were used as laxative and purgative [64]. The plant was also used as febrifuge, vermifuge, anticonvulsant and against chicken pox, guinea worm and black quarter [65-67]. It was said that the infusion of the leaves of *C. occidentalis* is used as an effective treatment for hepatitis [68]. In Unani medicine it was used as an antidote of poisons, blood purifier, expectorant, anti-inflammatory agent and a remedy for the

treatment of liver diseases [69]. In India it was used for haematuria, rheumatism, typhoid, asthma and disorders of haemoglobin [70-71].

**Part used:** All parts of the plant were used medicinally [70].

### Physicochemical properties

Moisture 10%, total ash 7.4- 8.0%, acid insoluble ash 5.3-5.9%, and alcohol and water extractive values were 7.7% and 15.1% respectively [72-73].

### Chemical constituents

The plant contained crude protein 2.3%, crude fiber 20.8%, lipid 14.9% and carbohydrates 48.1% [27]. The phytochemical analysis showed that the different parts of the plant contained different chemical groups included alkaloids, anthocyanosides, phenolics, proteins, phlobatannins, steroids, tannins, flavonoids, anthroquinone, saponins, terpenes, resins, balsams, amino acids, carbohydrates, sugars and cardiac glycosides [60,67,73-83].

Many compounds were isolated from *Cassia occidentalis* included achrosin, aloe-emodin, emodin, anthrones, apigenin, aurantiobtusin, campesterol, cassiollin, chryso-obtusin, chrysophanic acid, chrysarobin, chrysophanol, chrysoeriol, rhein, aloe-amine, Kaempferin, isorhein, 1,8-dihydroxy-2-methyl anthraquinone, 1,4,5-trihydroxy-3-methyl-7-methoxy anthraquinone, cassiaoccidentalin A, B and C, achrosine, xanthorin, aurantiobtusin, campesterol, cassiollin, chryso-obtusin, chrysophanic acid, chrysarobin, chrysoeriol, funiculosin, galactopyranosyl, helminthosporin, islandicin, kaempferol, lignoceric acid, linoleic acid, linolenic acid, sitosterols, mannitol, mannopyranosyl, mattecucinol, obtusifolin, obtusin, oleic acid, physcion, apigenin, quercetin, rhamnosides, rhein and rubrofusarin [72,84-89].

Three new compounds were isolated from the seeds of *Cassia occidentalis* Linn. These compounds have been characterized as 5, 7-dihydroxyflavone-5-O- $\beta$ -D-xylopyranosyl-7-O- $\alpha$ -L-rhamnopyranosyl-(1 $\rightarrow$ 3)-O- $\alpha$ -L-arabinopyranoside ; 3, 5, 7, 3', 4'-pentahydroxy flavone-3-O- $\alpha$ -L-rhamnopyranosyl-7-O- $\beta$ -D-glucopyranosyl-(1 $\rightarrow$ 3)-O- $\beta$ -D-xylopyranoside and 5, 7, 3', 4'-tetrahydroxy-6-methoxyflavone-5-O- $\alpha$ -L-arabinopyranosyl-(1 $\rightarrow$ 4)-O- $\alpha$ -L-rhamnopyranosyl-(1 $\rightarrow$ 3)-O- $\beta$ -D-galactopyranoside <sup>(90)</sup>. Two new anthraquinone glycosides viz. 1,3-dihydroxy-6,7,8-trimethoxy-2-methylanthraquinone 3-O- $\alpha$ -rhamnopyranosyl(1 $\rightarrow$ 6)- $\beta$ -glucopyranosyl (1 $\rightarrow$ 6)- $\beta$ -galactopyranoside and 1-hydroxy-3,6, 7, 8-tetramethoxy-2-methylanthraquinone 1-O- $\alpha$ -rhamnopyranosyl (1 $\rightarrow$ 6)- $\beta$ -glucopyranosyl (1 $\rightarrow$ 6)- $\beta$ -galactopyranoside have been isolated from the leaves of *Cassia occidentalis*. Glycosides 3,2'-dihydroxy-7,8,4'-trimethoxy-flavone-5-O- $\beta$ -D-glucopyranosyl (1 $\rightarrow$ 2); - $\beta$ -D-galacto-pyranoside and

apigenin-7-O- $\beta$ -D-allopyrano-side have been isolated from *Cassia occidentalis* [91-92].

*Cassia occidentalis* extract contained total flavonoids 3.24 $\mu$ g/g, carotenoids 2.9 $\mu$ g/g and total phenolics 6.7 $\mu$ g [93].

The physical and chemical constants of *Cassia occidentalis* oils were: ( total yield: 1.0%, iodine value: 114.5, thiocyanogen value: 74.0, saponification equivalent: 283.0), liquid fatty acids (yield % 74.9, iodine value: 151.3, saponification equivalent: 280.5), solid fatty acids (yield % of the total 25.1, iodine value:3.8, saponification equivalent: 287.8) and saturated acids (yield % of the total 24.0) [94].

Mineral composition of defatted flour of *Cassia occidentalis* were included Ca 3.81, Na 0.11, K 1.86, Mg 0.81 and Fe 16.44 mg/100g [73].

## PHARMACOLOGICAL EFFECTS

### Antimicrobial, antifungal, antiparasitic and insecticidal effects:

*Cassia occidentalis* showed strong antimicrobial activity against *Staphylococcus aureus*, *Bacillus subtilis*, *B. protens* and *Vibrio cholerae*. Leaves of *Cassia occidentalis* were extracted with ethanol and water. The extracts were used to carry out antimicrobial screening *in vitro* on *Staphylococcus aureus*, *Pseudomonas aeruginosa*, *Escherichia coli*, *Salmonella typhi*, *Shigella spp*. The result showed that these extracts were effective against all tested organisms. The highest activity (diameter of the zone of inhibition was about 18mm) was demonstrated by the ethanol extract of *Cassia occidentalis* leaves against *Salmonella typhi* while the lowest activity (7mm) exerted by the water extract against *Shigella spp*. On the other hand the ethanol extract were not active against *E. coli* at all concentration. The water extract showed inhibition at lower concentration (30 and 60mg/ml) against *E. coli* and *Salmonella typhi* [79].

The antibacterial activity of the hexane, methanol, chloroform and water extracts of *Cassia occidentalis* was tested against *E. coli*, *P. multocida*, *S. typhi*, *S. typhimurium*, *S. pyogenes*, *S. pneumoniae* and *K. pneumoniae*. The results showed that *E. coli* was the most susceptible microorganism [67].

The antibacterial activity of *Cassia occidentalis* flower extract was evaluated against *Klebsiella pneumoniae*, *Staphylococcus aureus*, *Streptococcus pneumoniae* and *Pseudomonas aeruginosa*. The results showed that all the extracts had activity against *Klebsiella pneumoniae* at a concentration between 30-90 mg/ml. The minimum inhibitory concentration ranged between 35-55 mg/ml for water extract and 25-55 mg/ml for chloroform extract. The minimum bactericidal concentration was 55 mg/ml by both water and chloroform extract [81].

Antibacterial activity (against *Staphylococcus aureus*, *Bacillus subtilis*, *Proteus vulgaris* and *Pseudomonas aeruginosa*) and antitubercular activities

was evaluated for petroleum ether, benzene, chloroform and methanol extracts of *Cassia occidentalis* leaves. Several fractions of *C. occidentalis* extracts showed good antibacterial activity (MIC: 2–8  $\mu$ g/ml) and moderate antitubercular activity (MIC 25-50  $\mu$ g/ml). Antibacterial activity of various extracts of *Cassia occidentalis* L. seeds was evaluated against three respiratory tract pathogens (*Staphylococcus aureus* MTCC 1144, *Streptococcus pneumoniae* MTCC 655 and *Streptococcus pyogenes* MTCC 442). The results showed that methanol extract was more active antibacterial than other extracts. The zone of inhibition exhibited by methanol extract against tested microorganisms ranged between 20.9 $\pm$ 0.21 to 23.1 $\pm$ 0.15 mm [74, 95-96].

The rate of release of sodium and potassium ions by aqueous and ethanolic extract of leaves of *Cassia occidentalis*. Was Investigated Forsome selected pathogenic bacteria in the genera *Bacillus*, *Staphylococcus*, *Echerichia*.

*Streptococcus*, *Klebsiella*, *Pseudomonas* and *Salmonella* using flame photometer. The aqueous extract was found to be more effective in the leakage of Na<sup>+</sup> and K<sup>+</sup> ions than the ethanolic extract for all organisms investigated except *Salmonella*. The aqueous extract released 2.66 ppm sodium ions on *Pseudomonas aeruginosa*, whereas ethanolic extract released 13.3 ppm, while the K<sup>+</sup> ions released were 9.282 and 49.980 ppm for ethanolic and aqueous extract, respectively. Comparison of the amount of Na<sup>+</sup> and K<sup>+</sup> ions release by the plant extract with two commercial antibiotic (chloramphenicol and tetracycline) showed that the latter gives a higher value than the former. For sodium ion, *Bacillus subtilis* gives 167 ppm and 164 ppm for chloramphenicol and tetracycline respectively where as 2.28 and 3.42 ppm were released by ethanolic and aqueous extract of the *Cassia occidentalis* respectively. There was no significant difference in the amount of leaked Na<sup>+</sup> ions and potassium ions between the two antibiotics. For Na<sup>+</sup> [97].

Crude extracts of different parts (leaf, seed and pod) of *Cassia occidentalis* was examined for their antifungal activity against three fungi viz. *Candida albicans*, *Aspergillus clavatus* and *Aspergillus niger*. Antifungal activity of different plant parts in terms of minimal inhibitory concentration ranged between 200-1000  $\mu$ g/ml. The extracts performed as good as or even better than the standard drugs nystatin and griseofulvin with exception of activity of leaf extracts against *Aspergilli* [98].

The anthelmintic activity of ethanolic extract of *Cassia occidentalis* was evaluated using adult earthworm *Pheritima posthuma*. Various concentrations (25, 50, 75 mg/ml) of all extracts were tested and the results were expressed in terms of time for paralysis and time for death of worms. Dose dependent activity was observed in all extracts *Cassia occidentalis* [99].

*In vitro* egg hatch assay and larval development tests were conducted to determine the possible anthelmintic effects of crude aqueous and hydro-alcoholic extracts of the leaves of *Cassia occidentalis*. The aqueous extract of *Cassia occidentalis* induced complete inhibition of egg hatching at concentration less than or equal to 1 mg/ml. Aqueous and hydro-alcoholic extracts of *Cassia occidentalis* shown statistically significant and dose dependent egg hatching inhibition. The plant extracts have shown remarkable larval development inhibition. Aqueous extracts of *Cassia occidentalis* induced 96.36% inhibition of larval development [100].

Antimalarial effects of *Cassia occidentalis* was documented by many studies [101-103]. The ethanolic, dichloromethane and lyophilized aqueous extracts of *Cassia occidentalis* root bark were evaluated for their antimalarial activity *in vivo*, in 4-day, suppressive assays against *Plasmodium berghei* ANKA in mice, no toxic effect or mortality was observed in mice treated, orally, with any of the extracts as a single dose of 500 mg/kg body weight, or as the same dose given twice weekly for 4 weeks (to give a total dose of 4 g/kg). No significant lesions were observed, by eye or during histopathological examinations, in the hearts, lungs, spleens, kidneys, livers, large intestines or brains of the mice. At doses of 200 mg/kg, the ethanolic and dichloromethane extracts produced significant chemosuppressions of parasitaemia (of > 60%). The lyophilized aqueous extract was less active than the corresponding ethanolic extract [101].

The larvicidal potential of ethanol extract of *Cassia occidentalis* was tested against the larvae of *Anopheles stephensi*. The ethanol extract of *Cassia occidentalis* was found most effective with LC<sub>50</sub> value was 60.69%-92.21%. The smoke toxicity was more effective against the *Anopheles stephensi*. Smoke exposed gravid females oviposited fewer eggs when compared to those not exposed [104].

The leaves of *Cassia occidentalis* were used to protect cowpea seeds (*Vigna unguiculata*) against *Callosobruchus maculatus*. The biological activity of the leaves, the seeds and oil of *C. occidentalis* was evaluated against *C. maculatus*. At the rate of 10 % (w/w), both fresh and dry leaves as well as whole and ground seeds had no contact toxicity on the cowpea beetle. In contrast, seed oil increased mortality of *C. maculatus* eggs and first larval instar at the concentration of 10 ml/kg cowpea [105].

The larvicidal effect of methanolic extract of *Cassia occidentalis* leaf, at various concentrations was evaluated against malarial vector (mosquito larva). The plant extract exhibited larvicidal activity at different time intervals (24 hrs and 48 hrs). The mosquito larva of LC<sub>50</sub> and LC<sub>90</sub> values of *Cassia occidentalis* for I instar larvae were 60.69%, 119.74%, for the II instar were 64.76%, 121.60%, for the III instar were 67.78%, 123.35%, for the

IV instar were 70.56%, 122.81% and for pupa were 92.21%, 162.52% respectively [106].

*Cassia occidentalis* ethanolic leaves extract was evaluated for its effectiveness to suppress wood damage by workers termite (Isoptera: Rhinotermitidae). Bioassay was conducted in plastic containers. Extract was prepared into different concentration (0.5, 1.0 and 1.5 g) and inoculated into separate plastic containers containing 20 g of disinfested wood sample which correspond to 2.5, 5.0 and 7.5% w/w, respectively. Forty workers termite were introduced into these containers. Mortality of the insect was assessed after 24h interval. The result showed that *C. occidentalis* ethanolic extracts in all concentrations caused mortality of the workers termite within the shortest duration of application when compared with the untreated wood. 100% mortality of workers termite was observed on wood treated with *C. occidentalis* extract at all level of application after 120h of treatment [107].

#### Antianxiety and antidepressant effects

The antianxiety and antidepressant activity of the ethanolic and aqueous extracts of *Cassia occidentalis* leaves (500 mg/kg, orally) was evaluated in rodents. Antianxiety activity was tested by exposing rats to unfamiliar aversion in different methods like elevated plus maze model and actophotometer. In elevated plus-maze test, the ethanolic and aqueous extracts of *Cassia occidentalis* leaves at a dose of 500 mg/kg orally, significantly increased the number of entries and time spent into the open arm. The magnitude of the antianxiety effects 500 mg/kg orally, of ethanolic and aqueous extracts of *Cassia occidentalis* was comparable to that of diazepam 5 mg/kg ip. The average of basal activity scores after 30 and 60 min of administration of ethanolic and aqueous extracts of *Cassia occidentalis* leaves 500 mg/kg orally, showed significant reduction of the locomotor activity. The antidepressant activity was tested by using despair swim test and tail suspension test. In despair swim test apparatus, the ethanolic and aqueous extracts of leaves of *Cassia occidentalis* at a dose of 500 mg/kg orally, significantly decreased the immobility time. The magnitude of the antidepressant effects of 500 mg/kg orally, of ethanolic and aqueous extracts of leaves of *Cassia occidentalis* was comparable to that of fluoxetine 10 mg/kg ip. In tail suspension test, the ethanolic and aqueous extracts of leaves of *Cassia occidentalis* at a dose of 500 mg/kg orally, significantly decreased the immobility time. The magnitude of the antidepressant effects of 500 mg/kg orally, of ethanolic and aqueous leaves of *Cassia occidentalis* was comparable to that of fluoxetine 10 mg/kg ip. Ethanolic extract of *Cassia occidentalis* leaves showing more significant antidepressant activity over the aqueous extract [76].

Geriforte, a combination of several plant ingredients (including *Cassia occidentalis*) is being used in India as a restorative tonic in old age. This preparation was

evaluated for anti-stress (adaptogenic) activity by inducing various stressful situations in animals. The survival time of swimming mice increased with different doses of Geriforte. The drug also prevented changes in adrenals (increase in weight and reduction of ascorbic acid and cortisol contents) induced by stress (5 hr swimming). Both restrain and chemically-induced ulcers were prevented by 100 mg/kg of Geriforte. Furthermore, pretreatment with Geriforte prevented the increase of liver weight and volume induced by carbon tetrachloride and also the milk-induced leucocytosis. Gradual and constant increase in body weight was observed in the rats taking the drug. However, no effect was observed on spontaneous motor activity and body temperature. It has some central nervous system stimulant activity as judged by the reduction of hexobarbital sleeping time. The LD<sub>50</sub> as determined in acute toxicity studies on mice was between 5-6 g/kg orally [108].

#### Antidiabetic effects

The methanolic extract of *C. occidentalis* leaves was tested against alloxan-induced diabetic mice. The diabetes in the experimental mice was induced by a single intraperitoneal injection of alloxan. Treatment with *C. occidentalis* leaf extract at different doses (200 mg/kg, 300 mg/kg, and 450 mg/kg orally) significantly reduced the blood glucose level to normal in diabetic mice [109].

Methanol fraction of *C. occidentalis* leaves (COLMF) was tested against streptozotocin-induced diabetic rats. Oral administration of COLMF significantly and dose-dependently normalized hemoglobin, glycosylated hemoglobin, hepatic glycogen, lipid peroxidation, antioxidants (TBARS, HP, SOD, CAT, GPx VitC, VitE, GSH) and hepatic marker enzymes (ALT, AST, ALP, ACP) near to normal in STZ-diabetic rats ( $p < 0.05$ ). Histopathological examination showed that COLMF protected the pancreatic tissue from STZ-induced damage [77].

Aqueous extract of *C. occidentalis* produced a significant reduction in fasting blood glucose levels in the normal and alloxan-induced diabetic rats. Petroleum ether extract showed activity from day 14 and chloroform extract showed activity from day 7. Significant differences were observed in serum lipid profiles (cholesterol and triglyceride), serum protein, and changes in body weight by aqueous extract treated-diabetic animals, when compared with the diabetic control and normal animals. Concurrent histopathological studies of the pancreas of these animals showed comparable regeneration by extract which were earlier necrosed by alloxan [110].

Antidiabetic effect of the butanol (DTB) and aqueous (DTA) leaves extracts of *Cassia occidentalis* was evaluated in alloxan-induced diabetic mice. DTB group showed significant reduction in plasma glucose levels ( $95.2 \pm 7.46$ ). DTA group showed significant reduction ( $119.6 \pm 29.03$ ) but was less as compared with the DTB

group. DTB group showed significant reduction in plasma cholesterol levels ( $186 \pm 14.8$ ). DTA group ( $190 \pm 14.81$ ) also showed significant reduction but slightly less as compared with the DTB group. DTB group showed significant reduction in LDL levels ( $99.7 \pm 7.3$ ). Reduction in LDL levels in DTA group ( $111 \pm 5.1$ ) was also significant as compared to DTB group. However, both extracts didn't induced significant changes in HDL and triglycerides levels [111].

#### Effect on smooth muscles contraction

The relaxant effects of an aqueous extract of the leaf of *Cassia occidentalis* were investigated in rat aortic rings with or without intact endothelium. The extract inhibited contraction elicited by noradrenaline (NA) and potassium chloride (KCl) dose dependently. It also relaxed aortic rings precontracted with  $10^{-7}$  M NA and 50m M KCl. The induced relaxation did not require the presence of an intact vascular endothelium and was not affected by indomethacin (prostacylin inhibitor) and methylene blue [112].

The contractile responses of intestinal and lung parenchymal strips obtained from chickens treated with *Cassia occidentalis* extract were compared with those of the control group. Carbachol and histamine in graded concentrations were used as constrictor agonists for intestinal and lung parenchymal strips respectively, to determine cumulative concentration-effect relationships. For *in vivo* study, the extract was prepared by soaking the ground seeds overnight with 25 mM sodium bicarbonate containing 1% Triton X-100 and filtering it under vacuum. The birds were dosed orally at the dosage level of 1% body weight. The experimental design consisted of treating the birds for a period of one day, two days, three days, or five days. Control group of the same age were treated with 25 mM sodium bicarbonate containing 1% Triton X-100 at 1% body weight. The maximal responses of the treated birds decreased significantly compared to those of the control group. The decrease was also directly related to the length of treatment. The day 5 group showed the maximum decrease. The decrease in maximal response of lung parenchymal strip suggested the existence of an active principle(s) in the extract which caused the effect by systemic absorption. This *in vitro* study suggested involvement of smooth muscles as a primary site for the toxicosis caused by *Cassia occidentalis* [113].

#### Wound healing and sun protective effects

The wound healing property of methanolic crude extract of *Cassia occidentalis* leaves and a pure compound chrysophanol isolated from it, was evaluated in excision, incision and dead space wound models. The parameters studied included rate of wound contraction and the period of epithelialization in excision wound model. Tensile strength in incision wound model and granulation tissue dry weight in dead space model were assessed along with

histopathological examinations. Chrysophanol was found to possess significant wound healing property than methanol crude extract. This effect was evident by the decrease in the period of epithelialization, increase in the rate of wound contraction, skin breaking strength, granulation tissue dry weight content and breaking strength of granulation tissue. Histopathological study of the granulation tissue showed increased collagenation when compared to control group of animals [119].

The sun protection factor (SPF) for the flowers of *Cassia occidentalis* was studied. On comparison it was observed that *C. occidentalis* had high SPF value with antioxidant and antibacterial property. The results indicated that *Cassia occidentalis* flowers can be used as efficient antimelanocyte agent for UV radiation hazards [115].

#### Anti-inflammatory, analgesic and antipyretic effects

The anti-inflammatory activity of *Cassia occidentalis* leaf powder was assayed in male albino rats using carrageenan-induced rat paw edema. *C. occidentalis* was maximally active at a dose of 2000 mg/kg. In the cotton pellet granuloma assay, *Cassia occidentalis* leaf powder was able to suppress the transudative, exudative and proliferative components of chronic inflammation. Furthermore, *Cassia occidentalis* leaf powder was able to lower the lipid peroxide content and gamma-glutamyl transpeptidase and phospholipase A2 activity in the exudate of cotton pellet granuloma. The increased alkaline phosphatase activity and decreased A/G ratio of plasma in cotton pellet granulomatous rats were normalized after treatment with *Cassia occidentalis* leaf powder. *C. occidentalis* powder was able to stabilize the human erythrocyte membrane against hypotonicity-induced lysis [116].

The ethanol and water extracts of *Cassia occidentalis* leaves were screened for antinociceptive activity using acetic acid induced writhing test, hot plate test and tail immersion test in mice. The antipyretic potential of the extract was evaluated using yeast induced pyrexia method in rats. The results showed that ethanol and water extracts had significant ( $p < 0.01$ ) dose dependent antinociceptive and antipyretic properties at a dose of 150 and 300 mg/kg. The inhibition produced by the highest dose (300 mg/kg) of the extracts was significantly ( $P < 0.01$ ) lower than that by acetylsalicylic acid (100 mg/kg). Both the ethanolic and water extracts of *Cassia occidentalis* showed significant ( $P < 0.01$ ) effect on pyrexia induced by yeast [117].

#### Antioxidant effects

The antioxidant potency of the methanolic extracts of leaves, stems and seeds of *Cassia occidentalis* was investigated via *in vitro* system such as nitric oxide scavenging activity,  $\beta$ -carotene-linoleic acid model system, hydroxyl radical scavenging activity, reducing

power, metal chelating activity and superoxide radical scavenging activity. The methanolic extract of seed were found to have highest hydroxyl radical, superoxide radical and  $\beta$ -carotene-linoleic acid scavenging potential as compared to the leaves and stems extracts. However, methanolic leaves and stems extracts were found to possess highest metal chelating and nitric oxide radical scavenging potential in comparison with the seeds extract [118].

The antioxidant activity of various aqueous and organic extracts of *Cassia occidentalis* leaves was investigated *in vitro*. The extracts and the reference standard, butylated hydroxyl toluene (BHT) were evaluated for DPPH, nitric oxide, superoxide and hydroxyl radical scavenging activity. The methanolic extract exhibited significant antioxidant activity but petroleum ether and chloroform extracts of *Cassia occidentalis* did not show any significant antioxidant activity in comparison with standard (BHT) [119].

The antioxidant potential of different fractions of whole plant of *Cassia occidentalis* was also evaluated using various *in vitro* assay including 1, 1-Diphenyl-2-Picrylhydrazyl (DPPH), nitric oxide scavenging activity, hydrogen peroxide scavenging activity, reducing power assay. The various antioxidant activities were compared with ascorbic acid and gallic acid as standard antioxidant. The results showed that ethyl acetate fraction of whole plant of *Cassia occidentalis* possess significant antioxidant activity than benzene fraction and methanol fraction [120].

Chrysophanol isolated from *Cassia occidentalis* (50 mg/kg bw) and methanol fraction (COLMF) (200 mg/kg bw) were administered to rats with paracetamol induced hepatotoxicity for seven days. Oral administration of chrysophanol and COLMF significantly normalized the values of SOD, CAT, GPx, GSH, Vit-C and Vit-E [75]. The efficacy of ethanolic extract from *Cassia occidentalis* against  $\text{CCl}_4$  induced oxidative stress was tested using Wistar albino rats [121]. The antioxidant activity was assessed by monitoring the levels of lipid peroxides, antioxidant enzymes like glutathione peroxidase, glutathione reductase, glutathione-S transferase, superoxide dismutase, catalase, and non-enzymic antioxidants like reduced glutathione vitamin-C, vitamin-E, cereloplasmin and uric acid in the liver tissues. Administration of  $\text{CCl}_4$  increased the level of lipid peroxides, decreased the activities of enzymic and non-enzymic antioxidants. Pre-treatment with ethanolic extract significantly prevented the alterations induced by  $\text{CCl}_4$  and maintained a near normal antioxidant status. Decreased activities of enzymes in  $\text{CCl}_4$  intoxicated rats and their reversal in the ethanolic extract treated rats showed the potency of ethanolic extract in combating  $\text{CCl}_4$  induced oxidative stress [122].

#### Nephroprotective and hepatoprotective effects

The nephroprotective activity of the 70% hydroalcoholic extract of *Cassia occidentalis* was tested

against gentamicin induced nephrotoxicity in rats. The degree of protection was determined by estimating urinary creatinine, urinary glucose, urinary sodium, urinary potassium, blood urea, serum creatinine levels and body weight of the animals. The *in-vivo* antioxidant activity was determined by estimating the tissue levels of GSH, SOD, catalase and lipid peroxidation. The treatment with hydroalcoholic extract of *Cassia occidentalis* (200 and 400 mg/kg body weight) markedly reduced gentamicin induced elevation of urinary sodium, potassium electrolytes, urinary glucose, blood urea and creatinine levels. It also increased the body weights. The comparative histopathological study of kidney exhibited almost normal architecture as compared to control group. The deterioration in the antioxidant parameter associated with gentamicin induced nephrotoxicity in rats was also attenuated by 70% hydroalcoholic extract of *Cassia occidentalis*. 70% hydroalcoholic extract of *Cassia occidentalis* showed a dose dependent increase in the level of GSH. However, 200 mg/kg showed 23.3% increase and 400 mg/kg showed 51.4.7% increase in GSH levels. treatment with 70% hydroalcoholic extract of *Cassia occidentalis* significantly elevated the SOD ( $p < 0.001$ ) and catalase ( $p < 0.001$ ) [123].

The hepatoprotective effect of aqueous and aqueous-ethanolic extract (50% v/v) of leaves of *Cassia occidentalis* was studied on rat liver damage induced by paracetamol and ethyl alcohol by monitoring serum transaminase (aspartate amino transferase and serum alanine amino transferase), alkaline phosphatase, serum cholesterol, serum total lipids and histopathological alterations. The extract of leaves of the plant produced significant hepatoprotection by restoring the liver functions [80,124].

Chrysophanol isolated from *Cassia occidentalis* (50 mg/kg bw) and methanol fraction (COLMF) (200 mg/kg bw) were administered to rats with paracetamol induced hepatotoxicity for seven days. Oral administration of chrysophanol and COLMF significantly normalized the values of SOD, CAT, GPx, GS H, Vit-C and Vit-E. The elevated serum enzymatic levels of AST, ALT, ACP and ALP were significantly restored towards normalization by pre-treatment with chrysophanol and COLMF ( $p > 0.05$ ). The histopathological studies also confirmed the hepatoprotective nature of the extracts. The results of this study strongly indicate that *Cassia occidentalis* has potent hepatoprotective action against paracetamol induced hepatic damage in rats [121].

#### Antimutagenic effects

The antimutagenic potential of aqueous extract of *Cassia occidentalis* against the chromosomal aberrations (CA) produced *in vivo* by benzo[a]pyrene (B[a]P) and cyclophosphamide (CP) in mice was investigated. Male mice were treated with three doses of plant extract (50

mg/kg, 250 mg/kg and 500 mg/kg) for 7 days prior to the administration of single dose of mutagens (B[a]P 125 mg/kg oral; CP 40 mg/kg ip). The results indicated that *C. occidentalis* was not genotoxic per se and exerted no other toxic signs and symptoms in treated animals. The chromosomal aberrations produced by B[a]P and CP were significantly reduced ( $p < 0.001$ ) by *C. occidentalis* pre-treatment. Furthermore, animals treated with plant extract showed a reduced level of cytochrome P450 and elevated levels of glutathione S-transferase activity and glutathione content in the liver [125].

#### Immunological effects

The protective effect of *Cassia occidentalis* against cyclophosphamide (CP)-induced immunosuppression was evaluated in animal models. Swiss albino male mice were treated orally with the aqueous extract of *C. occidentalis*, 100 mg/kg, body weight, for 14 days. Cyclophosphamide was given intraperitoneally in a single dose of 50 mg/kg bw. Body weight, relative organ weight, lymphoid organ cellularity, hemagglutination titre (HT), plaque forming cell (PFC) assay and quantitative hemolysis of SRBC (QHS) were studied in these animals. CP showed suppressive effects on lymphoid organ weight and cellularity and other parameters of humoral immunity. Plant extract treatment itself produced no toxicity. The administration of plant extract to CP-exposed animals resulted in improved humoral responses. *C. occidentalis* treatment significantly ( $P < 0.01$ ) enhanced PFC response in CP-treated animals. In QHS assay, *C. occidentalis* also showed protection in CP-treated animals. Bone marrow cell counts, which were reduced in CP-treated animals, were reversed significantly ( $p < 0.01$ ) to normal levels in CP + plant extract group animals [126].

The effects of *Cassia occidentalis* (CO) on rat mast cell degranulation inhibition and human red blood cell (HRBC) membrane stabilization were studied *in vitro*. The anti lipid peroxidant effects of CO were also studied *in vitro*. Effect of CO on carrageenan-induced mouse paw oedema inhibition was also assessed. CO significantly decreased maximum protection of 80.8% at 15 microg/ml. The extract also caused significant reduction in malondialdehyde (MDA) levels of murine hepatic microsomes at 100 microg/ml (56%) and significantly reduced carrageenan induced inflammation in mice at a dose of 250 mg/kg [127].

The effects of the treatment with seeds of *C. occidentalis* and its external tegument fraction (TE) on the development of chicks and their lymphoid organs bursa of Fabricius and spleen were studied. Chicks that received a commercial ration with 1% TE had reduced body and lymphoid organ weights. The bursa of Fabricius presented reduction in the diameters of the follicles, and in the thickness of the cortical and medullary regions. The spleen presented depleted lymphoid tissue in the white pulp.



These results indicate that the active principle of *C. occidentalis* is more concentrated on its TE fraction, and that it can cause weight loss as well as alterations in the lymphoid organs in chicks [128].

The possible immunotoxic effects of *Cassia occidentalis* (Co) seeds were studied through incorporation of seeds in broiler chicken rations at different concentrations (0.0%, 0.25%, 0.50% and 0.75%), for 28 or 42 days. The innate immune function (macrophage activities of spreading, phagocytosis, peroxide and nitric oxide production) and acquired immune function (humoral and cellular immune responses), as well as lymphoid organ weights and pathology were evaluated. There was enhanced macrophage activity, increased hydrogen peroxide production ( $P < 0.05$ ) in cells of birds given 0.75% Co, but there were no other pro-inflammatory effects. Birds receiving 0.75% of Co in ration for 42 days gained less weight ( $P < 0.01$ ), and showed a decrease in relative weight of the bursa of Fabricius ( $P < 0.05$ ) and spleen ( $P < 0.01$ ). In addition, morphological changes were also noted in these lymphoid organs, with depletion of lymphoid cells on the spleen and bursa of Fabricius, resulting in lower relative weight of both lymphoid organs. No impairment of humoral immune response against Newcastle disease and in cellular immune response after a phyto-haemagglutinin challenge was recorded. The authors postulated that mitochondrial damage and related apoptosis may be responsible for the enhanced peroxide production and the reduced relative weight of the bursa of Fabricius and spleen [129].

### Toxic and adverse effects

The clinical and histopathological findings of an outbreak of *C. occidentalis* poisoning in horses was studied. Twenty mares were poisoned after consuming ground corn contaminated 8% of *C. occidentalis* seeds. Of the 20 animals affected, 12 died, 2 died 6h after the onset of clinical signs which compatible with hepatic encephalopathy and other animals were subjected to euthanasia 12h after the onset of the clinical signs. However, the remaining 8 mares presented with mild depression and decreased appetite, but improved with treatment and no clinical sequelae were observed. In 6 animals that underwent a necropsy, an enhanced hepatic lobular pattern was noted and a large number of seeds were observed in the large intestine. Hepatocellular pericentrolobular necrosis and cerebral oedema were the main histological findings. In one mare, there was mild multifocal semi-membranous rhabdomyocytic necrosis and haemorrhage. Seeds collected from intestinal contents and sifted from the culpable feedstuff were examined. Examination of the leaves, flowers, fruits and seeds of the resultant plant identified *C. occidentalis*. Horses poisoned by *C. occidentalis* seeds demonstrate clinical signs associated with hepatoencephalopathy and frequently die

suddenly. Lesions primarily involve the liver and secondarily, the central nervous system [130].

Several animal studies have documented that fresh or dried beans are toxic. Ingestion of large amounts by grazing animals has caused serious illness and death. The toxic effects in large animals, rodents and chicken are on skeletal muscles, liver, kidney and heart. The predominant systems involved depend upon the animal species and the dose of the beans consumed. Brain functions were often affected. Gross lesions at necropsy consist of necrosis of skeletal muscle fibers and hepatic centrilobular necrosis; renal tubular necrosis was less frequent. Muscle and liver cell necrosis was reflected in biochemical abnormalities. The median lethal dose  $LD_{50}$  is 1 g/kg for mice and rats. Toxicity is attributed to various anthraquinones, their derivatives and alkaloids [57].

A 20-day subchronic oral toxicity of *C. occidentalis* seeds and beverage was evaluated in male and female albino mice. Raw or roasted seeds of *C. occidentalis* were administered in the diet of one group of mice at dose levels of 0 and 100g/kg/day for 20 days, while 1ml of water or of beverage prepared from raw or roasted seeds was administered two-time daily to another group. The addition of raw seeds to the diet had significant ( $p \leq 0.05$ ) effects with clinical signs including weight body loss, increase of liver enzymes (GOT and GPT) activity and serum ammonia level, decrease of serum protein level and increase of Hepato-somatic-index. Addition of roasted seeds in the diet or administration of beverages prepared from the seeds had no clinical signs attributable to the test compound. The results indicate that roasting and extraction, the two key operations in the process of *C. occidentalis* beverage; eliminate the toxicity of the seeds. It is suggested that roasting destroys the toxin and water which is used as solvent during the infusion was inefficient to extract the toxin from the grounded seeds [131].

A pre-clinical safety evaluation of hydroalcoholic extract of *Cassia occidentalis* stem and leaf was carried out in male and female Wistar rats. In acute toxicity tests, the effect of hydroalcoholic extract of *Cassia occidentalis* stem and leaf in three doses 0.625, 1.25, 2.5 and 5.0 g/kg orally, on general behavior was studied. Adverse effects and mortality were recorded for up to 14 days. In subacute toxicity assays, animals received *Cassia occidentalis* by gavage at the doses of 0.10, 0.50 or 2.5 g/kg/day for 30 days and biochemical, hematological and morphological parameters were determined. *Cassia occidentalis* did not produce any hazardous symptoms or death in the acute toxicity test, showing  $LD_{50}$  higher than 5 g/kg. Subacute treatment with *Cassia occidentalis* failed to change body weight gain, food and water consumption and hematological and biochemical profiles. In addition, no changes in macroscopical and microscopical aspect of organs were observed in the animals [132].

The toxic effects of prolonged administration of *Cassia occidentalis* (Co) seeds were evaluated in rats.

Groups of rats were fed rations containing 1%, 2% and 4% Co seeds for a period of 2 weeks. The rats of the experimental groups showed lethargy, weakness, recumbency, depression and emaciation. Two rats of the 4% group died during the experiment. Histopathological study showed fiber degenerations in the skeletal (Tibial, pectoral and diaphragm) and cardiac muscles. The liver parenchyma showed vacuolar degeneration and, the kidney showed mild nephrosis in the proximal convoluted tubules. All of these alterations occurred in a dose-dependent fashion. Moderate to severe degeneration and spongiosis were observed in the central nervous system, especially in cerebellum. Electron microscopy revealed mitochondrial lesions in all analyzed tissues [133].

The aqueous extract showed hypoproteinaemic effect in rats. ALT, AST and ALP levels were significantly elevated ( $P < 0.05$ ). Hypoproteinaemic effects, and increase in ALT, AST and ALP indicate that the crude extract of *C. occidentalis* leaves is toxic [78].

The effects of oral sub-acute administration of *Cassia occidentalis* during pregnancy was investigated in female Wistar rats. Pregnant rats were treated orally from the 1<sup>st</sup> to the 6<sup>th</sup> day (pre-implantation period) and from the 7<sup>th</sup> to the 14<sup>th</sup> day (organogenic period) of pregnancy, with doses of 250 and 500 mg/kg. On the 20<sup>th</sup> day of pregnancy, the reproductive parameters were evaluated. The results revealed no statistically significant differences between the control and treated groups in terms of offspring/dam relationship, fetuses, placentae and ovaries weights, number of implantation and resorption sites, number of corpora lutea in the ovaries and pre- and post-implantation loss rates. However, the presence of dead fetuses was registered in both doses of 250 and 500 mg/kg of *Cassia occidentalis*. Accordingly, the use of *Cassia occidentalis* is not recommended during pregnancy [134].

The toxic effect of administering ground *Cassia occidentalis* seeds was investigated in rabbits in different concentrations (1%, 2%, 3% and 4%) for 30 days. The toxic effects of the plant were evaluated on the basis of weight gain, histopathological, biochemical and morphometric parameters, as well as histochemistry and electron microscopy. Animals that received the ration containing 4% ground *C. occidentalis* seeds gained less weight ( $p < 0.05$ ) and died in the third week. Histopathology revealed that the heart and liver were the main organs affected, with myocardial necrosis and centrilobular degeneration. There was a reduction in cytochrome oxidase activity in the glycogenolytic fibers, together with muscle atrophy. Electron microscopy of the liver cells revealed

dilated mitochondria, with destruction of the internal cristae [135].

In investigate of the peripheral nerve involvement in the acute intoxication of chicks with *C. occidentalis* seeds; it appeared that individual fibers revealed signs of extensive axonal damage with myelin ovoids. Sections confirmed the axonal damage, axons were filled with membranes, some residual disorganized filaments, and enlarged mitochondria. In some instances the axon disappeared and there was secondary degeneration of the myelin sheath [136].

Histochemical and electron microscopic studies of biceps femoris, pectoralis major and rectus femoris of chronically treated birds with seeds of *Cassia occidentalis* (0.2% external/internal tegment), were performed. Electron microscopy examination showed enlarged mitochondria with disrupted or excessively branched cristae [137].

Various anthraquinones and their derivatives like emodin glycosides, toxalbumins, and other alkaloids are usually blamed for *C. occidentalis* toxicity [17, 92]. Animal experimental studies have calculated a lethal dose ( $LD_{50}$ ) of 1 g/kg for mice and rats when aqueous extract of the plant was injected intraperitoneally [124].

An annual seasonal outbreaks of acute hepato-myoecephalopathy in young children (Nine children died within 4-5 days) in western Uttar Pradesh for causal, were found to be association with *Cassia occidentalis* poisoning [139].

Data on human toxicity are extremely scarce. The clinical spectrum and histopathology of *C. occidentalis* poisoning in children resemble those of animal toxicity, affecting mainly hepatic, skeletal muscle and brain tissues. The case-fatality rate in acute severe poisoning is 75-80 per cent in children [140].

**Dosage:** Seed: 3-6g powder; Leaf: 10-20 ml juice; Root bark 50-100 ml decoction [141].

## CONCLUSION

There are many reports supported the potential use of *C. occidentalis* seed as alternative food or medicinal ingredient because of its wide pharmacological effects, but also there are many reports blame its seed as the cause of intoxication to various domestic animals and human. The toxicological studies and the detection of the therapeutic index were highly recommended to detect the degree of its toxicity in comparison with the therapeutic benefit. However, the potential adverse effects may need detoxification options for safe usage.

## REFERENCES

1. Al-Snafi AE. Central nervous and endocrine effects of Myristica fragrans. 4<sup>th</sup> Arabic Conf. of Medicinal plants, Thamar Univ. Yemen 1999, 111-121.
2. Al-Snafi AE. The Methods followed by Arabic physicians for treatment of cancer 4<sup>th</sup> Arabic Conf. of Medicinal Plants, Thamar Univ. Yemen 1999, 122-136.

3. Al-Snafi AE, Al-Trikrity AH, Ahmad RH. Hypoglycemic effect of *Teucrium polium* and *Cyperus rotundus* in normal and diabetic rabbits. *Med J Tikrit Univer*, 9(2), 2003, 1-10.
4. Marbin MI, Al-Snafi AE, Marbut MM, Allahwerdy IY. The probable therapeutic effects of Date palm pollens in treatment of male infertility. *Tikrit Journal of Pharmaceutical Sciences*, 1 (1), 2005, 30-35.
5. Al-Snafi AE, Al-Samarai AGM, Al-Sabawi AM. The effectiveness of *Nigella sativa* seed oil in treatment of chronic urticaria. *Tikrit Journal of Pharmaceutical Sciences*, 1(1), 2005, 1-6.
6. Al-Snafi AE, Museher TR. Hypnotic, muscle relaxant, and anticonvulsant effects of *Myristica fragrans*. *Journal of Thi Qar College of Medicine*, 2(1), 2008, 18-23.
7. Al-Snafi AE. A negative feedback mechanism between brain catecholamines and gamma amino butyric acid, could be a central defense mechanism in stress. A review article. *Global Journal of Pharmacology*, 7 (2), 2013, 103-108.
8. Al-Snafi AE. Chemical constituents and pharmacological activities of *Ammi majus* and *Ammi visnaga* a review. *International Journal of Pharmacy and Industrial Research*, 3 (3), 2013, 257-265.
9. Al-Snafi AE. Pharmacological effects of *Allium* species grown in Iraq. An overview. *International Journal of Pharmaceutical and health care Research*, 1(4), 2013, 132-147.
10. Al-Snafi AE. Chemical constituents and pharmacological activities of milfoil (*Achillea santolina*) A Review. *Int.J.PharmTech Res*, 5(3),2013, 1373-1377.
11. Al-Snafi AE. The pharmaceutical importance of *Althaea officinalis* and *Althaea rosea* A Review. *Int J PharmTech Res*, 5(3), 2013, 1387-1385.
12. Al-Snafi AE, Faris AN. Anti-inflammatory and antibacterial activities of *Lippia nodiflora* and its effect on blood clotting time. *J.Thi-Qar Sci*, 4(1), 2013, 25-30.
13. Al-Snafi AE. The pharmacology of *Bacopa monniera*. A review. *International Journal of Pharma Sciences and Research*, 4(12), 2013, 154-159.
14. Al-Snafi AE. The Pharmacological Importance of *Bauhinia variegata*. A review. *Journal of Pharma Sciences and Research*, 4(12), 2013, 160-164.
15. Al-Snafi AE. The Pharmacological importance of *Benincasa hispida*. A review. *Journal of Pharma Sciences and Research*, 4(12), 2013, 165-170.
16. Al-Snafi AE. The Chemical constituents and pharmacological effects of *Bryophyllum calycinum*. A review. *Journal of Pharma Sciences and Research*, 4(12), 2013, 171-176.
17. Al-Snafi AE. The Pharmacological activities of *Alpinia galangal* - A review. *International Journal for Pharmaceutical Research Scholars*, 3(1-1), 2014, 607-614.
18. Al-Snafi AE. Chemical constituents and pharmacological activities of *Arachis hypogaea*. – A review. *International Journal for Pharmaceutical Research Scholars*, 2014; 3(1-1): 615-623.
19. Al-Snafi AE. The Pharmacological importance and chemical constituents of *Arctium Lappa*. A review. *International Journal for Pharmaceutical Research Scholars*, 3(1-1), 2014, 663-670.
20. Al-Snafi AE. The pharmacology of *Apium graveolens*. - A review. *International Journal for Pharmaceutical Research Scholars*, 3(1-1), 2014, 671-677.
21. Al-Snafi AE. The pharmacology of *Anchusa italica* and *Anchusa strigosa* – A review. *International Journal of Pharmacy and Pharmaceutical Sciences*, 6(4), 2014, 7-10.
22. Al-Snafi AE. The pharmacological importance of *Anethum graveolens* – A review. *International Journal of Pharmacy and Pharmaceutical Sciences*, 6(4), 2014, 11-13.
23. Al-Snafi AE, Wajdy JM, Tayseer Ali Talab. Galactagogue action of *Nigella sativa* seeds. *IOSR Journal of Pharmacy*, 4(6), 2014, 58-61.
24. Al-Snafi AE. The chemical constituents and pharmacological effects of *Adiantum capillus-veneris*- A review. *Asian Journal of Pharmaceutical Science and Technology*, 5(2), 2015, 106-111.
25. Al-Snafi AE. The pharmacological and therapeutic importance of *Agrimonia eupatoria*- A review. *Asian Journal of Pharmaceutical Science and Technology*, 5(2), 2015, 112-117.
26. Al-Snafi AE. The chemical constituents and pharmacological effects of *Ammannia baccifera* - A review. *International Journal of Pharmacy*, 5(1), 2015, 28-32.
27. Al-Snafi AE. The chemical contents and pharmacological effects of *Anagallis arvensis* - A review. *International Journal of Pharmacy*, 5(1), 2015, 37-41.
28. Al-Snafi AE, Hanaon RM, Yaseen NY, Abdulalhussain WS. Study the anticancer activity of plant phenolic compounds. *Iraqi Journal of Cancer & Medical Genetics*, 4(2), 2011, 66-71.
29. Al-Snafi AE. The pharmacological importance of *Artemisia campestris*- A review. *Asian Journal of Pharmaceutical Research*, 5(2), 2015, 88-92.
30. Al-Snafi AE. Chemical constituents and pharmacological effects of *Asclepias curassavica* – A review. *Asian Journal of Pharmaceutical Research*, 5(2), 2015, 83-87.

31. Al-Snafi AE. The pharmacological importance of *Asparagus officinalis* - A review. *Journal of Pharmaceutical Biology*, 5(2), 2015, 93-98.
32. Al-Snafi AE. The medical importance of *Betula alba*- An overview. *Journal of Pharmaceutical Biology*, 5(2), 2015, 99-103.
33. Al-Snafi AE. Bioactive components and pharmacological effects of *Canna indica*- An Overview. *International Journal of Pharmacology and toxicology*, 5(2), 2015, 71-75.
34. Al-Snafi AE. The chemical constituents and pharmacological effects of *Capsella bursa-pastoris* - A review. *International Journal of Pharmacology and toxicology*, 5(2), 2015, 76-81.
35. Al-Snafi AE. The pharmacological importance of *Ailanthus altissima*- A review. *International Journal of Pharmacy Review and Research*, 5(2), 2015, 130-136.
36. Al-Snafi AE. *Alhagi maurorum* as a potential medicinal herb: An overview. *International Journal of Pharmacy Review and Research*, 5(2), 2015, 121-129.
37. Al-Snafi AE. The pharmacological importance of *Aloe vera*- A review. *International Journal of Phytopharmacy Research*, 5(2), 2015, 28-33.
38. Al-Snafi AE. The constituents and biological effects of *Arundo donax*- A review. *International Journal of Phytopharmacy Research*, 5(2), 2015, 34-40.
39. Al-Snafi AE. The nutritional and therapeutic importance of *Avena sativa* - An overview. *International Journal of Phytotherapy*, 5(2), 2015, 48-56.
40. Al-Snafi AE. The Pharmacological Importance of *Bellis perennis* - A review. *International Journal of Phytotherapy*, 5(2), 2015, 63-69.
41. Al-Snafi AE. The chemical constituents and pharmacological effects of *Capparis spinosa* - An overview. *Indian Journal of Pharmaceutical Science and Research*, 5(2), 2015, 93-100.
42. Al-Snafi AE. The chemical constituents and pharmacological effects of *Carum carvi* - A review. *International Journal of Pharmaceutical Science and Research*, 5(2), 2015, 72-82.
43. Al-Snafi AE. The pharmacological importance of *Casuarina equisetifolia*- An overview. *International Journal of Pharmacological Screening Methods*, 5(1), 2015, 4-9.
44. Al-Snafi AE. The chemical constituents and pharmacological effects of *Chenopodium album*- An overview. *International J of Pharmacological Screening Methods*, 5(1), 2015, 10-17.
45. Al-Snafi AE, Bahaadeen EF, Marbeen MI, Marbut MM. The effect of date palm pollens and zinc sulphate in the treatment of human male infertility. *Tikrit Journal of Pharmaceutical Sciences*, 2(1), 2006, 31-34.
46. Al-Snafi AE. Encyclopedia of the constituents and pharmacological effects of Iraqi medicinal plants. Thi qar University, 2013.
47. Germplasm resources information network. United States Department of Agriculture, 2004.
48. Muyibi SA, OLolorede BR, Hanelt P, Büttner R, Mansfeld R. Encyclopedia of agricultural and horticultural. *Springer*, 1986, 563-564.
49. Manandhar S. Plants and people of Nepal. Hongkong. *Timber Press*, 2002, 140.
50. Neuwinger HD. African ethnobotany: poisons and drugs: chemistry, pharmacology, toxicology. *Weinheim, Chapman & Hall*, 1996, 287-293.
51. Huang KC, Williams WM. The pharmacology of Chinese herbs. Boca Raton, CRC Press 1999, 84.
52. United State Department of Agriculture, Natural resources conservation service, *Senna occidentalis* (L.), <http://plants.usda.gov/core/profile?symbol=seoc2>
53. Lorenzi H. Plantas Daninhas do Brasil. Nova Odessa. San Paulo, Brazil, 1982.
54. USDA-NRCS. The Plants Database, Version 3.5. National Plant Data Center, Baton Rouge, USA, 2002, <http://plants.usda.gov>.
55. Holm LG, Pancho JV, Herberger JP, Plucknett DL. A Geographical Atlas of World Weeds. New York, USA, 1979.
56. International Legume Database and Information Service. University of Southampton, UK, 2002. <http://www.ildis.org/database/>.
57. Vashishtha VM, John TJ, Kumar A. Clinical & pathological features of acute toxicity due to *Cassia occidentalis* in vertebrates. *Indian J Med Res*, 130(1), 2009, 23-30.
58. Raghunatam K, Mitra R. Pharmacognosy of indigenous drugs . New Delhi: Central council for research in Ayurveda and Siddha, 1, 1982, 529.
59. Mugisha MK, Origa HO. Traditional herbal remedies used in management of sexual impotence and erectile dysfunction in Western Uganda. *African Health Sciences*, 5(1), 2005, 40-49.
60. Veerachari U, Bopaiah AK. Phytochemical investigation of the ethanol, methanol and ethyl acetate leaf extracts of six *Cassia* species. *International Journal of Pharma and Bio Sciences*, 2(2), 2012, 260-270.
61. Krithikar KR, Basu BD. *Cassia occidentalis*, Indian Medicinal Plants, 1999, 860.

62. The Wealth of India. A dictionary of Indian Raw Material and Industrial Products. New Delhi, 1998, 350.
63. Tropical plant database- Fedegoso (*Cassia occide*), 2008.
64. Todd RG. Senna and other purgatives. In: Extra pharmacopoeia Martindale, London, 1967, 1266-1267.
65. Mann A, Gbate M, Umar AN. *Senna occidentalis* (Linn.). Medicinal and Economic Plants of Nupe land, 2003, 41.
66. Iwu MM. Catalogue of major medicinal plants. Handbook of African Medicinal Plants CRC Press, London, 1993.
67. Saganuwan AS, Gulumbe ML. Evaluation of *in-vitro* antimicrobial activities and phytochemical constituents of *Cassia occidentalis*. *Animal Research International*, 3(3), 2006, 566-569.
68. Onakpa MM, Owoleke OE. A Survey of medicinal plants used in the management of diabetes mellitus in North central Nigeria. *Biological and Environmental Sciences Journal for the Tropics*, 7(4), 2010, 124-127.
69. Nadkarni AK. Indian Materia Medica, 3<sup>rd</sup> edition, Popular Press Prakashnan Pvt. Ltd, Mumbai, India, 1976.
70. Frodin DG. History and concepts of big plant genera. *Taxon*, 53(3), 2004, 753-776.
71. Singh S, Singh SK, Yadav A. A review on Cassia species: Pharmacological, traditional and medicinal aspects in various countries. *American Journal of Phytomedicine and Clinical Therapeutics*, 1(3), 2013, 291-312.
72. Vijayakshimi S, Ranjitha J, Devi Rajeswari V, Bhagiyalakshmi M. Pharmacological profile of *Cassia occidentalis*- A review. *International Journal of Pharmacy and Pharmaceutical Sciences*, 5(3), 2013, 29-33.
73. Daniyan SY, Abalaka ME, Aransiola SA, Elemba OM. Phytochemical screening, proximate analysis and mineral composition of *Cassia occidentalis* seed extract. *Asian Journal of Pharmaceutical and health Sciences*, 1(3), 2011, 145-147.
74. Yeragamreddy PR, Peraman R, Chilamakuru NB, Routhu H. *In vitro* Antitubercular and Antibacterial activities of isolated constituents and column fractions from leaves of *Cassia occidentalis*, *Camellia sinensis* and *Ananas comosus*. *Afr J Pharmacol Ther*, 2(4), 2013, 116-123.
75. Gowrisri M, Kotagiri S, Vrushabendra SBM, Archana SP, Vishwanath KM. Anti-oxidant and nephroprotective activities of *Cassia occidentalis* leaf extract against gentamicin induced nephrotoxicity in rats. *Research Journal of Pharmaceutical, Biological and Chemical Sciences*, 3 (3), 2012, 684-694.
76. Shafeen S, Srinath RT, Arafath S, Nagarjuna S, Padmanabha RY. Evaluation of antianxiety and antidepressant activity of *Cassia occidentalis* leaves. *Asian J PharmClin Res*, 5( Suppl 3), 2012, 47-50.
77. Emmanuel S. Rani MS, Sreekanth MR. Antidiabetic activity of *Cassia occidntalis* Linn. in streptozotocin- induced diabetic rats: A dose dependent study. *International Journal of Pharma and Bio Sciences*, 1(4), 2010, B14-B25.
78. Nuhu AA, Aliyu R. Effects of *Cassia occidentalis* aqueous leaf extract on biochemical markers of tissue damage in rats. *Tropical Journal of Pharmaceutical Research*, 7 (4), 2008, 1137-1142.
79. Sadiq IS, Shuaibu M, Bello AB, Tureta SG, Isah A, Izuagie T, Nasiru S, Kamaru MB. Phytochemistry and antimicrobial activities of *Cassia occidentalis* used for herbal remedies. *Journal of Chemical Engineering*, 1(1), 2012, 38-41.
80. Sastry AVS, Sastry VG, Appalanaidu B, Srinivas K, Annapurna A. Chemical and pharmacological evaluation of aqueous extract of seeds of *Cassia occidentalis*. *Journal of Chemical and Pharmaceutical Research*, 3(2), 2011, 566-575.
81. Daniyan SY, Oloruntimelehin JB, Ifeadi O. Antibacterial activity of *Cassia occidentalis* flower vegetable extract on selected bacteria. *Asian Journal of Biomedical and Pharmaceutical Sciences*, 1(1), 2011, 23-27.
82. Ranjithkuma J, Sivasankari K, Sekar T. Secondary metabolites investigation and its derivatives on *Cassia occidentalis*. *Journal of Chemical and Pharmaceutical Research*, 2(4), 2010, 371-377.
83. Ajagbonna OP, Onyeyili PA, Osunkwo VA, Muhammed BY. Acute toxicity and phytochemical studies of *cassia occidentalis* Linn extract in rats. *Sokoto of Journal o Veterinary Sciences*, 2(2), 2000, 32-35.
84. Yadav JP, Arya V, Yadav S, Panghal M, Kumar S, Dhankhar S. *Cassia occidentalis* L.: a review on its ethnobotany, phytochemical and pharmacological profile. *Fitoterapia*, 81(4), 2010, 223-230.
85. Ginde BS, Hosangadi BD, Kudav NA, Nayak KV, Kulkarni AB. Chemical investigations on *Cassia occidentalis* L. Isolation and structure of cassiolin, a new xanthone. *Journal of the Chemical Society*, 9, 1970, 1285-1289.
86. Oliver BB. Medicinal plants in tropical West Africa. Cambridge University Press, Cambridge, London, New York, New Rochelle, Melbourne Sydney, 1986, 148.
87. Shah CS and Shinde MV. Phytochemical studies of seeds of *Cassia tora* L. and *C. occidentalis* L. *Indian Journal of Pharmacy*, 32, 1969, 70.
88. Jawahar L, Gupta PC. Two new anthraquinones from the seeds of *Cassia occidentalis* Linn. *Cell Mol Life Sci*, 30(8), 1974, 850-851.
89. Tsutomu H, Seiki M, Hideyuki I, Takashi Y. C-Glycosidic flavonoids from *Cassia occidentalis*. *Phytochem*, 52(7), 1999, 1379-1383.
90. Yadava RN, Satnami DK. Chemical constituents from *Cassia occidentalis* Linn. *Indian Journal of Chemistry-Section B (IJC-B)*, 50B, 2011, 1112-1118.

91. Chauhan D, Chauhan JS, Siddiqui IR, Singh J. Two new anthraquinone glycosides from the leaves of *Cassia occidentalis*. *Indian Journal of Chemistry-Section B (IJC-B)*, 40B, 2011, 860-863.
92. Hatano T, Mizuta S, Ito H and Yoshida T. C-glycosidic flavonoids from *Cassia occidentalis*. *Phytochemistry*, 52(7), 1999, 1379-1383.
93. Ambikapathy SAV, Selvam AP. Studies on the phytochemistry, antimicrobial activity and antioxidant properties of *Cassia occidentalis* L. *Asian Journal of Plant Science and Research*, 2 (4), 2012, 530-533.
94. Farooq MO, Aziz MA, Ahmad MS. Seed oil from *Cassia fistula*, *C. occidentalis* and *C tora* (Indian varieties). *The Journal of American Oil Chemistry Society*, 1956, 21-23.
95. Weiser PA. Animal Research and Development in Animal disease control in Eastern Sudan 39, 1994, 139-149.
96. Gautam R, Navneet SS. Antibacterial and phytochemical analysis of *Cassia occidentalis* L. seeds against respiratory tract pathogens. *Indian Journal of Natural Products and Resources (IJNPR)*, 5(1), 2014, 52-55.
97. Oladunmoye MK, Adetuyi FC, Akinyosoye FA. Release of sodium and potassium ions by aqueous and ethanolic extract of *Cassia occidentalis* on some selected bacteria. *Trends in Applied Sciences Research*, 2(1), 2007, 85-87.
98. Davariya VS, Vala AK. Antifungal activity of crude extracts of *Cassia occidentalis*. *Int J Res Phytochem Pharmacol*, 1(2), 2011, 36-38.
99. Sayyad RR, Kare RD, Jagtap SM, Katkar ST, Kadam JH. Anthelmintic activity of ethanolic extract of *Cassia Occidentalis* Linn. *Int J Pharm Res Sci*, 2(1), 2014, 42-46.
100. Eguale T, Tadesse D, Giday M. *In vitro* anthelmintic activity of crude extracts of five medicinal plants against egg-hatching and larval development of *Haemonchus contortus*. *J Ethnopharmacol*, 137(1), 2011, 108-113.
101. Tona L, Mesia K, Ngimbi NP, Chrimwami B, Okond'ahoka, Cimanga K, de Bruyne T, Apers S, Hermans N, Totte J, Pieters L, Vlietinck AJ. In-vivo antimalarial activity of *Cassia occidentalis*, *Morinda morindoides* and *Phyllanthus niruri*. *Ann Trop Med Parasitol*, 95(1), 2001, 47-57.
102. Tona L, Ngimbi NP, Tsakala M, Mesia K, Cimanga K, Apers S. Antimalarial activity of 20 crude extracts from nine African medicinal plants used in Kinshasa Congo. *J Ethnopharmacol*, 68, 1999, 193-203.
103. Tona L, Cimanga RK, Mesia K, Musuamba CT, De Bruyne T, Apers S. *In vitro* antiplasmodial activity of extracts and fractions from seven medicinal plants used in the Democratic Republic of Congo. *J Ethnopharmacol*, 93, 2004, 27-32.
104. Dhandapani A, Kadarkarai M. HPTLC quantification of flavonoids, larvicidal and smoke repellent activities of *Cassia occidentalis* L. (Caesalpiniaceae) against malarial vectore *Anopheles stephensi* Lis (Diptera: Culicidae). *J Phytol phytopharmacol*, 3(2), 2011, 60-72.
105. Lienard V, Lognay G, Gaspar C, Severin M, Seck D. Biological activity of *Cassia occidentalis* L. against *Callosobruchus maculatus* (F.) (Coleoptera: Bruchidae). *Journal of Steroid product Research*, 29, 1993, 94-97.
106. Venkateswarlu G, Manoranjan S, Sharada N, Sravan Prasad M, Azeez MD, Rajeshwari E. Comparison of anti-larvicidal activity of *Cassia occidentalis*, *Bamboosa vulgaris* and *Sapindus mukurossi*. *Asian J Pharm Res*, 2(1), 2012, 118-119.
107. Abdullahi N, Yahya S, Yushau M, Tukur Z. Laboratory evaluation of the effect of *Khaya senegalensis* and *Cassia occidentalis* ethanolic leaves extracts against worker termites (Isoptera: Rhinotermitidae) on treated wood sample. *Journal of Stored Products and Postharvest Research*, 3(11). 2012, 152-155.
108. Singh N, Nath R, Mishra N. An experimental evaluation of anti-stress effects of Geriforte (an ayurvedic drug). *Quarterly Journal of Crude Drug Research*, 3, 1978, 125-132.
109. Onakpa MM, Ajagbonna OP. Antidiabetic potentials of *Cassia occidentalis* leaf extract on alloxan induced diabetic albino mice. *International Journal of PharmTech Research*, 4(4), 2012, 1766-1769.
110. Verma L, Khatri A, Kaushik B, Patil UK, Pawar RS. Antidiabetic activity of *Cassia occidentalis* (Linn) in normal and alloxan-induced diabetic rats. *Indian J of Pharmacology*, 42(4), 2010, 224-228.
111. Singh PS, Salwan C, Mann AS. Evaluation of anti-diabetic activity of leaves of *Cassia occidentalis*. *International Journal of Research in Pharmacy and Chemistry*, 1(4), 2011, 904-913.
112. Ajagbonna OP, Mojiminiyi FBO, Sofola OA. Relaxant effects of the aqueous leaf extract of *Cassia occidentalis* on rat aortic rings. *Afr J Biomed Res*, 4, 2001, 127- 129.
113. Venugopalan CS, Flory W, Hebert CD, Tucker TA. Assessment of smooth muscle toxicity in *Cassia occidentalis* toxicosis. *Veterinary and Human Toxicology*, 26(4), 1984, 300-302.
114. Sheeba M, Emmanuel S, Revathi K, Ignacimuthu S. Wound healing activity of *Cassia occidentalis* L in albino Wistar rats. *International Journal of Integrative Biology*, 8(1), 2009, 1-6.
115. Jayanthi V, Shafna A. Use of flowers as antimelanocyte agent against UV radiation effects. *American J of Bio-pharm Biochem and Life Sci*, 1 (Suppl 1), 2012, A68.
116. Sadique J, Chandra T, Thenmozhi V, Elango V. Biochemical modes of action of *Cassia occidentalis* and *Cardiospermum halicacabum* in inflammation. *J Ethnopharmacol*, 19(2), 1987, 201-212.
117. Sini KR, Sinha BN, Karpakavalli M, Sangeetha PT. Analgesic and antipyretic activity of *Cassia occidentalis* Linn. *Annals Biol Res*, 2(1), 2011, 195-200.

118. Arya V, Yadav JP. Antioxidant properties of methanol extracts of leaves, seeds and stem of *Cassia occidentalis*. *Research Journal of Medicinal plants*, 2011, 1-10.
119. Koche DK, Shirsat RP, Bhadange DG, Kamble LH. *In-vitro* antioxidant and radical scavenging activity of *Cassia occidentalis* L. leaf extracts. *Deccan Current Science*, 3(II), 2010, 204-208.
120. Vadnere GP, Patil AV, Jain SK, Wagh SS. Investigation on *in-vitro* antioxidant activity of whole plant of *Cassia occidentalis* Linn. (Caesalpinaceae). *International Journal of Pharm Tech Research*, 3(4), 2011, 1985-1991.
121. Rani AS, Emmanuel S, Sreekanth M, Ignacimuthu S. Evaluation of *in vivo* antioxidant and hepatoprotective activity of *Cassia occidentalis* Linn against paracetamol- induced liver toxicity in rats. *Int J Pharmacy Pharm Sci*, 2(3), 2010, 67-70.
122. Kumar AR, Abbulu K. Antioxidant activity of ethanolic extract of *Cassia occidentalis* against carbon tetrachloride induced oxidative stress in Wistar rats. *Int J Chem Sci*, 9(1), 2011, 378-386.
123. Gowrisri M, Kotagiri S, Vrushabendra SBM, Archana SP, Vishwanath KM. Anti-oxidant and nephroprotective activities of *Cassia occidentalis* leaf extract against gentamicin induced nephrotoxicity in rats. *Research Journal of Pharmaceutical, Biological and Chemical Sciences*, 3(3), 2012, 684-694.
124. Jafri MA, Jalis Subhani M, Javed K, Singh S. Hepatoprotective activity of leaves of *Cassia occidentalis* against paracetamol and ethyl alcohol intoxication in rats. *J Ethnopharmacol*, 66(3), 1999, 355-361.
125. Sharma N, Trikha P, Athar M, Raisuddin S. Protective effect of *Cassia occidentalis* extract on chemical-induced chromosomal aberrations in mice. *Drug Chem Toxicol*, 22(4), 1999, 643-653.
126. Bin-Hafeez B, Ahmad I, Haque R, Raisuddin S. Protective effect of *Cassia occidentalis* L. on cyclophosphamide-induced suppression of humoral immunity in mice. *J Ethnopharmacol*, 75(1), 2001, 13-18.
127. Sreejith G, Latha PG, Shine VJ, Anuja GI, Suja SR, Sini S, Shyama S, Pradeep S, Shikha P, Rajasekharan S. Anti-allergic, anti-inflammatory and anti-lipidperoxidant effects of *Cassia occidentalis* Linn. *Indian J Exp Biol*, 48 (5), 2010, 494-498.
128. Silva TC, Gorniak SL, Oloris SC, Raspantini PC, Haraguchi M, Dagli ML. Effects of *Senna occidentalis* on chick bursa of Fabricius. *Avian Pathol*, 32(6), 2003, 633-637.
129. Hueza IM, Latorre AO, Raspantini PC, Raspantini LE, Mariano-Souza DP, Guerra JL, Górnaiak SL. Effect of *Senna occidentalis* seeds on immunity in broiler chickens. *J Vet Med A Physiol Pathol Clin Med*, 54(4), 2007, 179-185.
130. Oliveira-Filho JP, Cagnini DQ, Badial PR, Pessoa MA, DelPiero Fand Borges AS. Hepatoencephalopathy syndrome due to *Cassia occidentalis* (Leguminosae, Caesalpinioideae) seed ingestion in horses. *Equine Vet J*, 45(2), 2013, 240-244.
131. Essa'a VJ, Medoua GN. Subchronic toxicity of the beverage made from *Cassia occidentalis* seeds in mice. *International Journal of Nutrition and Food Sciences*, 2(5), 2013, 237-242.
132. Silva MG, Aragão TP, Vasconcelos CF, Ferreira PA, Andrade BA, Costa IM, Costa-Silva JH, Wanderley AG, Lafayette SS. Acute and subacute toxicity of *Cassia occidentalis* L. stem and leaf in Wistar rats. *J Ethnopharmacol*, 136(2), 2011, 341-346.
133. Barbosa FM, Dagli ML, Maiorka PC, Górnaiak SL. Sub-acute intoxication by *Senna occidentalis* seeds in rats. *Food Chem Toxicol*, 43(4), 2005, 497-503.
134. Aragão TP, Lyra MM, Silva MG, Andrade BA, Ferreira PA, Ortega LF, da Silva SD, da Silva JC, Fraga MC, Wanderley AG, Lafayette SS. Toxicological reproductive study of *Cassia occidentalis* L. in female Wistar rats. *J Ethnopharmacol*, 123(1), 2009, 163-166.
135. Tasaka AC, Weg R, Calore EE, Sinhorini IL, Dagli ML, Haraguchi M, Górnaiak SL. Toxicity testing of *Senna occidentalis* seed in rabbits. *Vet Res Commun*, 24(8), 2000, 573-582.
136. Calore EE, Cavaliere MJ, Haraguchi M, Górnaiak SL, Dagli ML, Raspantini PC, Calore NM, Weg R. Toxic peripheral neuropathy of chicks fed *Senna occidentalis* seeds. *Ecotoxicol Environ Saf*, 39(1), 1998, 27-30.
137. Calore EE, Cavaliere MJ, Haraguchi M, Górnaiak SL, Dagli ML, Raspantini PC, Perez CNM. Experimental mitochondrial myopathy induced by chronic intoxication by *Senna occidentalis* seeds. *J Neurol Sci*, 146(1), 1997, 1-6.
138. Poisonous plants- *Cassia occidentalis*, <http://www.ces.ncsu.edu/depts/hort/consumer/poison/Cassioc.htm>, 2008.
139. Vashishtha VM, Kumar A, John TJ, Nayak NC. *Cassia occidentalis* poisoning causes fatal coma in children in Western Uttar Pradesh. *Indian pediatrics*, 44(17), 2007, 522-525.
140. Vashishtha VM, John TJ, Kumar A. Clinical and pathological features of acute toxicity due to *Cassia occidentalis* in vertebrates. *Indian J Med Res*, 130(1), 2009, 23-30.
141. Khare CP. Indian medicinal plants- An illustrated dictionary. *Springer Science and Business Media*, 2007, 129.