

Analgesic Activity and Safety Assessment of *Heliotropium indicum* Linn. (Boraginaceae) in Rodents

¹A. Boye, ²G.A. Koffuor, ³P. Amoateng, ²E.O. Ameyaw and ²A.K. Abaitey

¹Department of Medical Laboratory Technology, School of Physical Sciences,
University of Cape Coast, Cape-Coast, Ghana

²Department of Pharmacology, Faculty of Pharmacy and Pharmaceutical Sciences,
College of Health Sciences, Kwame Nkrumah University of Science and Technology, Kumasi, Ghana

³Department of Pharmacology and Toxicology, School of Pharmacy, College of Health Sciences,
University of Ghana, Legon-Accra, Ghana

Abstract: This study presented the analgesic and safety assessment of *Heliotropium indicum*, a plant traditionally used for the management of abdominal pains, dysmenorrhoea and post-labour inflammatory conditions in Ghana using formalin-induced pain model in mice. For comparison of analgesic effect, morphine (1-10 mg kg⁻¹) and diclofenac sodium (1-10 mg kg⁻¹) were used as a reference opioid and NSAID, respectively. The aqueous and ethanolic extracts (30-300 mg kg⁻¹) dose-dependently inhibited both the first and second phases of the formalin-induced nociception. Oral doses of the aqueous extract (1-5 g kg⁻¹) in imprint control region mice were well tolerated in acute toxicity studies; however a 14-day oral administration of 1-2 g kg⁻¹ of the extracts in sprague-Dawley rats produced pathologic effects on the heart, kidney, liver and lungs. Therefore, although the aqueous and ethanolic extracts of *H. indicum* have analgesic activity, it could have a cumulative toxic effects hence prolonged and continuous use is not advised.

Key words: Diclofenac, morphine, formalin-induced nociception, sub-acute toxicity

INTRODUCTION

Pain is an unpleasant feeling in response to acute tissue injury that induces the release of pain mediating substances like histamine, serotonin and substance (Ronald and Miller, 2005; Khoshraftar *et al.*, 2011). It may indicate an underlying pathological process (Baig *et al.*, 2009) and can significantly interfere with a person's quality of life and general functioning (Breivik, 2008). Pain can be classified as nociceptive and neuropathic. Nociceptive pain refers to the discomfort that results when a stimulus causes tissue damage to the muscles, bones, skin or internal organs. When most people think of pain, they think of nociceptive pain. Pain is the most common reason for physician consultation in the United States (Turk and Dworkin, 2004), a situation similar to that of Schim and Stang (2004). Pain is managed by opioid or non-opioid analgesics and non-steroidal anti-inflammatory drugs. These analgesics may be; available only to the urban dwellers, affordable to a minority of the population and associated with several adverse effects (Iroanya *et al.*, 2010). The study of plants that have been traditionally used as a painkiller should be seen as a

fruitful and logical research strategy, in the research for new analgesic drugs (Elisabetsky *et al.*, 1995; Khaksarian *et al.*, 2005).

One plant documented as being used extensively in traditional medical practice is *Heliotropium indicum* Linn (Family: Boraginaceae) commonly known in English as "Cock's comb" and called locally in Ghana as "Akonfem atiko" (Akan-Asante) (Burkill, 1985). This plant is widely distributed in West Africa, India and the Philippines. Its leaves have traditionally been used in medicine as abortifacients, ecbolics; antidotes (venomous stings, bites); arthritis, rheumatism, etc., eye treatments; fabrifuges; generally healing; naso-pharyngeal affections; pain-killers; paralysis, epilepsy, convulsions, spasm; pregnancy, antiabortifacients; skin, mucosae; vermifuges. The whole plant has activity against diarrhoea, dysentery; tumours and cancers and venereal diseases (Burkill, 1935; Ainslie, 1937; Dalziel, 1937; Quisumbing, 1951; Oliver, 1960; Irvine, 1961; Kugelman *et al.*, 1976; Burkill, 1985).

Although, *H. indicum* has been widely used traditional in medicine, there is virtually no scientific investigation into its use as an analgesic. It is in light and

in the quest for finding new and effective and affordable analgesics that the analgesic property of *H. indicum* is being investigated in ICR mice. Also, because of some reports linking *H. indicum* to toxic manifestations in broiler chicken in Australia with the disease characterized by depression, ascites and hepatic degeneration (Pass *et al.*, 1979) it is important that direct evidence be sought to ascertain its safety for use since it is extensively used in Ghana for many indications.

MATERIALS AND METHODS

Plant collection: The aerial parts of *H. indicum* were collected from Buokrom, a suburb of Kumasi (the capital of the Ashanti Region), Ghana, in September (2007) and authenticated by the Curator (Mr. Adator K. Brown) of the Department of Theoretical and Applied Biology, College of Sciences, KNUST, where a voucher specimen (KNUST/BSC / F621) has been deposited.

Animals and husbandry: Four-week old Inbred Control Region (ICR) mice obtained from the Department of Pharmacology, Animal House were housed stainless steel wire mesh cages and allowed to acclimatize with the laboratory environment over a two-week period. During this period, mice were observed (physical; in-life) and weighed daily. Individual weights of mice placed on test were within $\pm 22\%$ of the mean weight which was 30 g. The females were nulliparous and nonpregnant. The mice were kept under ambient light/dark cycle, room temperature and relative humidity. The animal had free access to pelleted mice chow (GAFCO, Tema, Ghana) and water.

Preparation of the ethanolic extract (HIE^E) and the aqueous extract (HIE^A) of *H. Indicum*: Sun-dried aerial parts of *H. indicum* were comminuted to coarse powder by a hammer mill. A 500 g quantity of the powder was cold macerated with 4 L of 70% alcohol in a glass-stopped flask for three days. The macerate was filtered to obtain a dark-brown filtrate. A Buchi Rotor Evaporator (Rotavapor R-210, Switzerland) was used to retrieve the alcohol leaving a dark-brown liquid which was dried in a Gallenkamp hot air oven (Oven 300 plus series, England). The percentage yield was 13.5%. This extract will be referred to in this study as HIE^E. A 600 g quantity of the coarse powder was also mixed with 5 L of water and warmed for 15 min. The infusion was filtered to obtain a dark-brown filtrate, concentrated by evaporation over a hot water bath and later in a hot air-oven at 60°C until a constant weight was obtained. It was cooled in a

desiccator to yield dark-brown solid extract which was named HIE^A and will be referred to in this study as such.

Preliminary phytochemical screening: HIE^E and HIE^A were screened for the presence of alkaloids, cyanogenic glycosides, tannins, saponins and steroids as described by Sofowora (1993), Harborne (1998) and Trease and Evans (1989).

Formalin-induced nociception: The formalin-induced nociception was carried out as described by Malmberg and Yaksh (1992) and Okokon *et al.* (2008). Experimental animals were put into thirteen groups with five per group. The groups were treated with either 30, 100 and 300 mg kg⁻¹ of HIE^E or HIE^A *per os*, 1, 3, 10 mg kg⁻¹ of morphine intraperitoneally, or 1, 3 and 10 mg kg⁻¹ diclofenac intraperitoneally. A vehicle treated group was the controls. Thirty to sixty min after drug treatment, nociception was induced by a subcutaneous injection of 0.1 mL of 5% formalin into the plantar tissues of the right hind paw of animals. Each animal was placed a perspex test chambers of dimensions 15×15×15 cm for observation for nociceptive behavior seen as licking and biting of the injected paw.

To observe and record the behavior of mice following the injection of formalin, a mirror was placed at 45° beneath the test chambers for unobstructive viewing of the animals and the nociceptive behaviors recorder for 60 min with a camcorder (Evario™ model GZ-MG1300, JVC, Tokyo, Japan) positioned in front of the mirror. With the aid of a movement tracking software, JWatcher™ Version 1.0 (University of California, Los Angeles, USA and Macquarie University, Sydney, Australia), nociceptive responses of each animal in each group were scored. The average nociceptive score for each time block was calculated by multiplying the frequency and duration of time spent licking the injected paw. Data was expressed as the mean scores between 0-10 and 10-60 min after the induction of nociception.

Toxicity studies: Following similarity in the analgesic effect of HIE^E and HIE^A (with HIE^A having more significant effect than HIE^E) and constraints with laboratory animal usage, the toxicity studies (i.e., acute and sub-acute tests) were investigated with HIE^A.

Acute toxicity test: ICR mice were placed into five groups with five animals in each group. The first four groups were given either 1, 2, 4 and 5 g kg⁻¹, *per os* of HIE^A. The last group was vehicle treated and was the control group. The animals in each group were observed hourly for 24 h for

acute toxicity symptoms such as changes in movement, salivation, respiratory pattern and frequency and consistency of stool, or mortality.

Sub-acute toxicity study: Four groups with five Sprague-Dawley rats in each group were used. Animals in the first three groups were dosed daily for fourteen days with either 0.5, 1 and 2 g kg⁻¹, *per os*, HIE^A. The last group was vehicle-treated group which served as control. Animals in each group were weighed before drug administration and on the seventh and fourteenth day of drug-treatment. Changes in body weights between the first, seventh and fourteenth days were recorded.

Blood samples were collected on the day-14 from animals in each group (by cardiac puncture) into ethylenediamine tetra-acetic acid (EDTA) tubes for haematological analysis using Sysmex haematology autoanalyzer (Model: KX-21N, Kobe, Japan) at the KNUST Hospital laboratory. The lung, liver, kidney and heart were collected, weighed and preserved in 10% phosphate buffered formalin for histopathological studies at the Department of Pathology, Komfo Anokye Teaching Hospital, Kumasi, Ghana. The organ-to-body weight ratios were determined.

Statistical analysis: GraphPad Prism Version 5.0 for Windows (GraphPad Software, San Diego, CA, USA) was used for all statistical analyses and plotting of the graphs. Data are presented as Mean±SEM and analyzed by One-way ANOVA followed by Dunnett's multiple comparison (post-hoc) test. $p \leq 0.05$ was considered statistically significant in all analysis.

RESULTS

Phytochemical screening: Phytochemical screening of HIE^E and HIE^A reveal the presence of alkaloids, cyanogenic glycosides, tannins, saponins and steroids.

Formalin-induced nociception test: The response to pain was biphasic comprising an initial intense response to pain beginning immediately after formalin injection and rapidly waning within 10 min (first phase). The first phase was then followed by a slowly rising but longer lasting response from 10-60 min after formalin injection with maximum effect at approximately 20-30 min after formalin injection (second phase). Administration of HIE^E and HIE^A inhibited significantly ($p \leq 0.05-0.01$) both first and second phases of formalin-induced nociception (Fig. 1, 2) similar to effects exhibited by diclofenac and morphine which were also significant inhibitions ($p \leq 0.05-0.01$) (Fig. 3, 4).

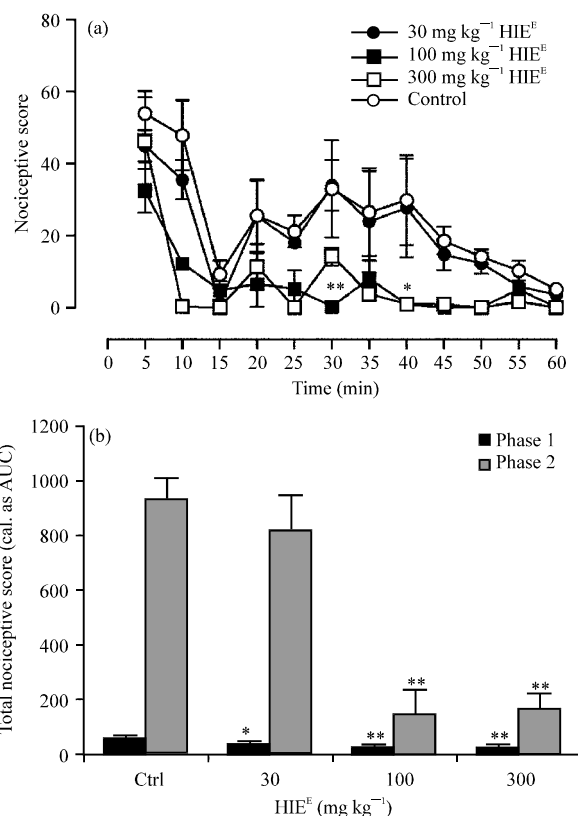


Fig. 1(a-b): Effect of HIE^E (30-300 mg kg⁻¹ p.o.) on (a) the time course and (b) the total nociceptive score calculated as area under the time-course curve (AUC) over both phases of formalin-induced nociception in mice. Each point/column is the Mean±SEM (n = 5). The significant differences between the treated and the control are indicated by * $p \leq 0.05$ and ** $p \leq 0.01$ (One-way ANOVA followed by Dunnett's multiple comparison test)

Analysis of the area under the time course curves (AUC) for HIE^E and HIE^A, morphine and diclofenac sodium revealed a dose-dependent effect.

Toxicity study: Administration of HIE^A did not cause mortality in experimental animals over the twenty four hours period of the acute toxicity. However mice in the 4 and 5 g kg⁻¹ HIE^A-treated groups initially displayed low spontaneous activity which waned after two hours. In the subacute toxicity study, none of the experimental animal died over the fourteen-day period. However, animals that received doses 1 and 2 g kg⁻¹ of HIE^A showed prostration from day 9-14 and were most of the time found gathered

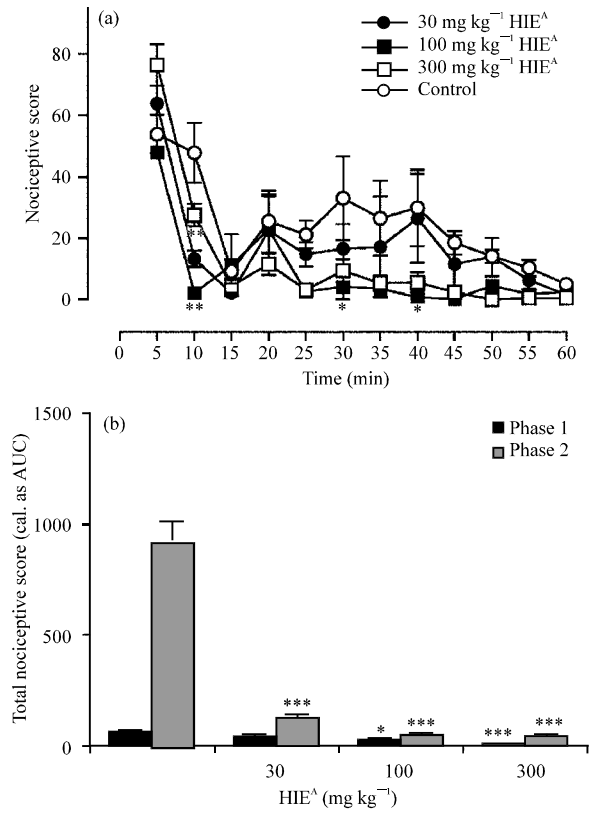


Fig. 2(a-b): Effect of HIE^A (30-300 mg kg⁻¹ p.o.) on the (a) Time course and (b) The total nociceptive score calculated as area under the time-course curve (AUC) over both phases of formalin-induced nociception in mice. Each point/column is the Mean±SEM (n = 5). The significant differences between the treated and the control are indicated by *p<0.05 and ***p<0.001 (One-way ANOVA followed by Dunnett's multiple comparison test)

together at the corners of the aluminium cages in which they were kept. The behavior and appearance of the 0.5 g kg⁻¹ HIE^A-treated animals were comparable to those of the control group over the entire fourteen-day period.

Change in body weight of HIE^A-treated animals between the first, seventh and the fourteenth day was not significantly different (p>0.05) from that of the control group. There was no significant change (p>0.05) in the wet weights of the heart and liver of HIE^A-treated mice compared to control. However, the wet weights of the lungs and kidney of HIE^A-treated mice showed significant increase (p<0.05-0.01) as compared to those of the control mice (Fig. 5). Investigations on haemoglobin

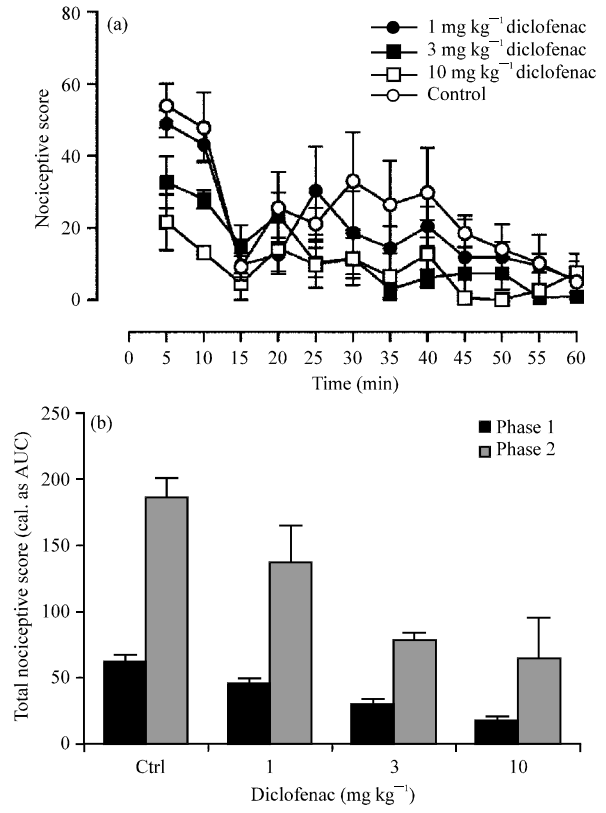


Fig. 3(a-b): Effect of diclofenac sodium (1-10 mg kg⁻¹ i.p.) on (a) The time course and (b) The total nociceptive score calculated as area under the time-course curve (AUC) over both phases of formalin-induced nociception in mice. Each point/column is the Mean±SEM (n = 5). The significant differences between the treated and the control are indicated by *p<0.05; **p<0.01 and ***p<0.001 (One-way ANOVA followed by Dunnett's multiple comparison test)

concentration, RBC count, WBC count and platelet concentration in hematological analysis did not show significant changes (p>0.05) between the control and HIE^A-treated animals (Table 1).

Histopathology: Histopathological examination reports on the liver of HIE^A-treated Sprague-Dawley rats from the KATH Pathology Department indicated marked vascular congestion with mild architectural distortions, mildly diffused vesicular steatosis and focal chronic inflammation with predominantly lymphocytic infiltration (Fig. 6). The lungs showed marked progressive changes of diffused alveolar haemorrhage and extensive oedema

Table 1: The effects of a 14-day oral administration of 0.5, 1.0 and 2.0 g kg⁻¹ HIE^A on the haematological profile of Sprague-Dawley rats

Parameters	Control	HIE ^A Treatments		
		0.5 g kg ⁻¹	1.0 g kg ⁻¹	2.0 g kg ⁻¹
WBC (x10 ⁹ L ⁻¹)	3.40±0.332	4.625±0.691	3.875±0.149	3.5±0.402
HGB (g dL ⁻¹)	15.15±0.2533	15.45± 0.4664	15.25±0.2327	15.85±0.2255
RBC (x10 ¹² L ⁻¹)	8.547±0.198	8.38±0.478	7.755±0.182	8.128±0.102
PLT (x10 ⁹ L ⁻¹)	619.25±70.2	756.0±34.907	618±49.25	642 ±13.979

Values are Means±SEM (n = 5). There were no significant changes (p>0.05) in measured parameters between the control and the treatment groups. The level of significance was established using One-Way Analysis of Variance (ANOVA) followed by Dunnett's multiple comparison's test

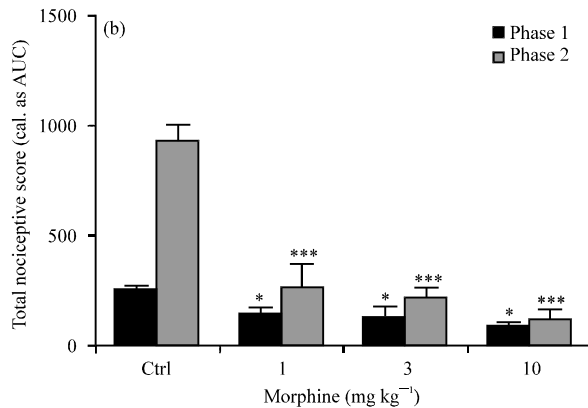
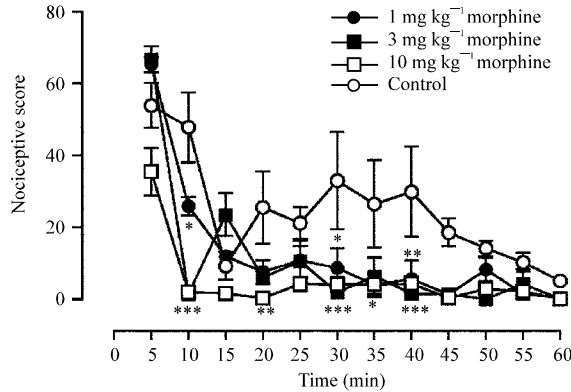


Fig. 4(a-b): Effect of morphine (1-10 mg kg⁻¹ i.p.) on (a) The time course and (b) The total nociceptive score calculated as area under the time-course curve (AUC) over both phases of formalin-induced nociception in mice. Each point/column is the Mean±SEM (n = 5). The significant differences between the treated and the control are indicated by *p<0.05 and ***p<0.001 (One-way ANOVA followed by Dunnett's multiple comparison test)

with rupture of inter alveolar septae and also bullae formation (Fig. 7). The kidney showed vascular congestion in the glomeruli with patchy focal chronic inflammation (Fig. 8) while the heart indicated diffused single cell necrosis with mild diffused chronic inflammation (Fig. 9).

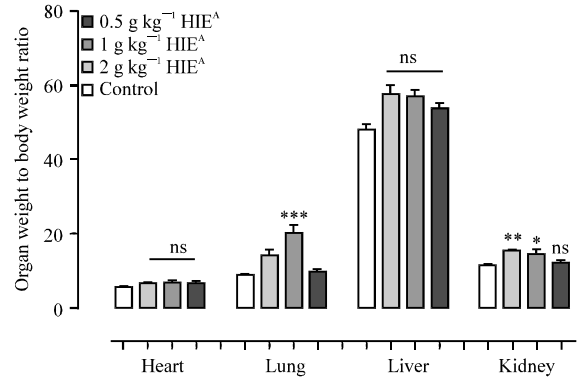


Fig. 5: The effect of a 14-days oral administration of HIE^A (0.5-2 g kg⁻¹) on the wet organ weights of Sprague-Dawley rats. Each column represents the Mean±SEM (n = 5). Significant changes in the mean of organ weights of treated animals compared to the controls was established using One-way Analysis of Variance (ANOVA) followed by Dunnett's post-hoc test. ns implies *p<0.05 **p<0.01 and ***p<0.001, ns: Not significant

DISCUSSION

The outcome of this study provides evidence that extracts of *H. indicum* possess analgesic properties but must be used with care. Extensive documentation on the use of natural compounds with different mechanisms of action can be used to treat diverse diseases (Rios *et al.*, 2009), especially from plants being used for such purposes. A number of plants traditionally used exhibit pharmacological properties with great potential in therapeutic applications (Da Rocha *et al.*, 2011). Both HIE^E and HIE^A exhibited analgesic properties in the formalin test similar to diclofenac and morphine used as positive controls. Widely used, the formalin test is a tonic model of continuous pain resulting from formalin-induced tissue injury. It is a useful model, particularly for the screening of novel compounds, since it encompasses inflammatory, neurogenic and central mechanisms of nociception (Ellis *et al.*, 1998). Results from the formalin test are

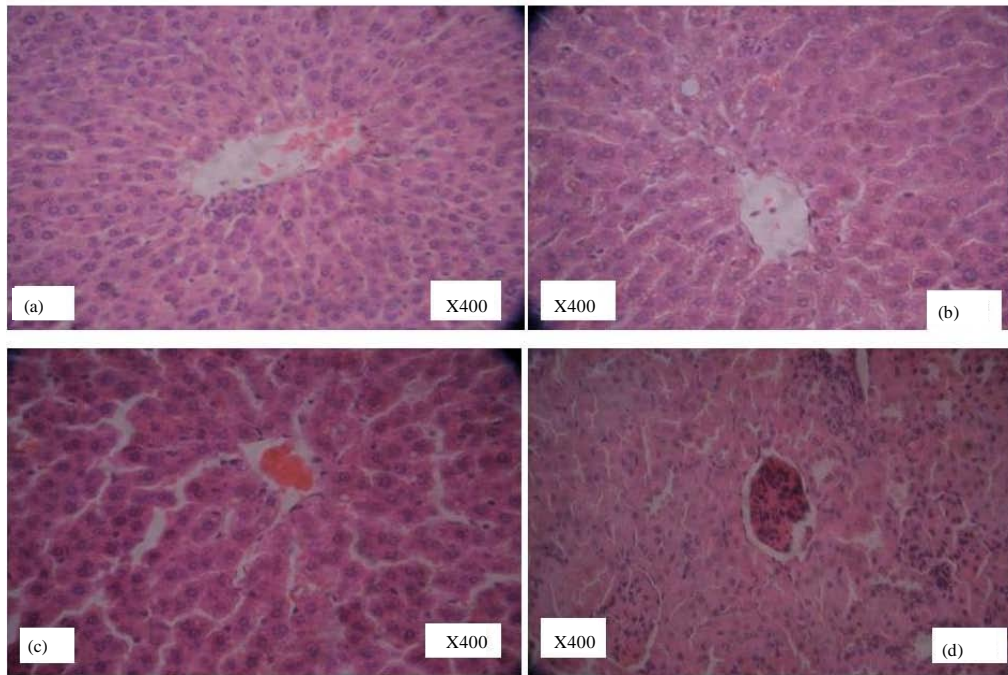


Fig. 6(a-d): Photomicrographs of the transverse section of the liver of HIE^A-treated rats. (a) is the control. b, c and d are for Sprague-Dawley rats treated with 0.5, 1 and 2 g kg⁻¹ of HIE^A, respectively over a period of 14 days. There is marked vascular congestion with mild architectural distortions Magnification: X400, Stain: Hematoxylin and Eosin

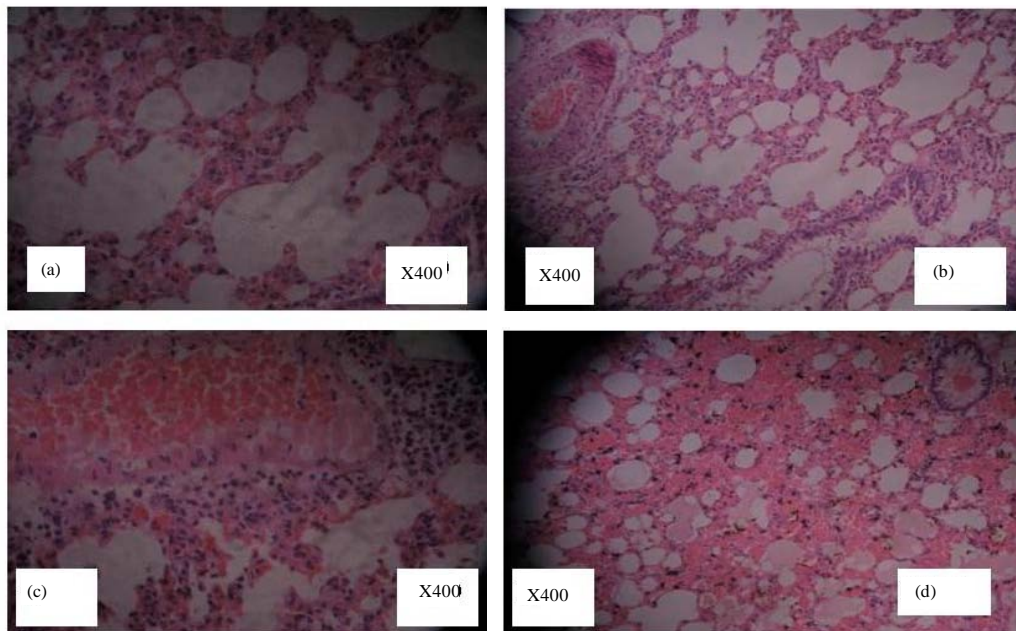


Fig. 7(a-d): Photomicrographs of the transverse section of the lungs of HIE^A-treated rats. (a) is the control. b, c and d are for Sprague-Dawley rats treated with 0.5, 1 and 2.0 g kg⁻¹ of HIE^A, respectively over a period of 14 days. There is diffused alveolar haemorrhage and extensive oedema with rupture of inter-alveolar septae. Magnification: X400, Stain: Hematoxylin and Eosin

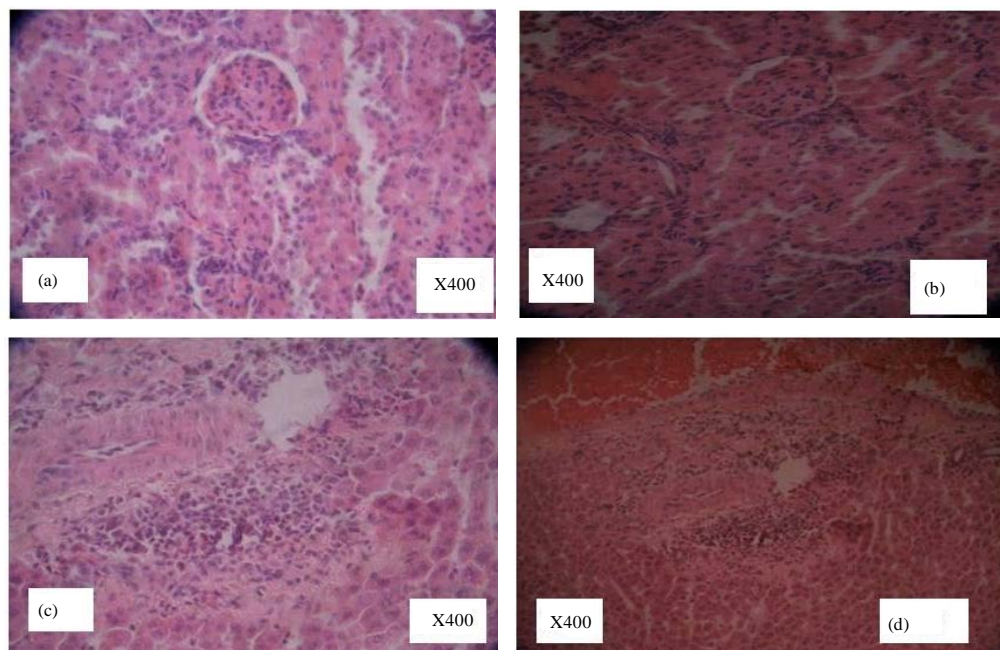


Fig. 8(a-d): Photomicrographs of the transverse section of the kidneys of HIE^A-treated rats. (a) is the control. b, c and d are for Sprague-Dawley rats treated with 0.5, 1 and 2.0 g kg⁻¹ of HIE^A, respectively over a period of 14 days. There is vascular congestion in the glomeruli with patchy focal chronic inflammation. Magnification: X400, Stain: Hematoxylin and Eosin

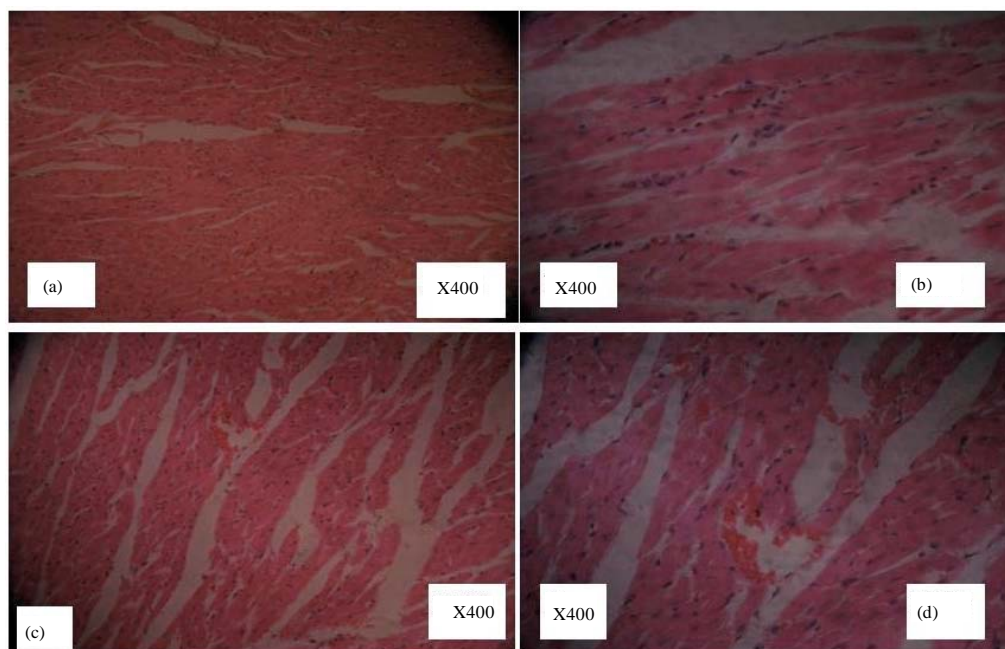


Fig. 9(a-d): Photomicrographs of the transverse section of the heart of HIE^A-treated rats. (a) is the control. b, c and d are for Sprague-Dawley rats treated with 0.5, 1.0 and 2.0 g kg⁻¹ of HIE^A, respectively over a period of 14 days. There is diffused single cell necrosis with mild diffused chronic inflammation. Magnification: X400, Stain: Hematoxylin and Eosin

usually better than those using mechanical or thermal stimulus (Tjolsen *et al.*, 1992; Woode *et al.*, 2009a). The test consists of two distinct phases; acute and chronic phase (Mohajer *et al.*, 2006; Zakaria *et al.*, 2006; Mokhtari *et al.*, 2007; Ibironke *et al.*, 2009). The first transient phase (neurogenic pain) is caused by the direct effect of formalin on sensory C-fibers and it is inhibited by narcotics while the second prolonged phase (inflammatory pain) is associated with the development of an inflammatory response and the release of nociceptive mediators (Woode *et al.*, 2009b). The second phase is inhibited by nonsteroidal anti-inflammatory drugs, narcotics and corticosteroids (Yaksh *et al.*, 2001). The analgesic properties of HIE^E and HIE^A observed may possibly be due to the inhibition of the direct effect of formalin on c-fibre nociceptors as well as inhibition of the synthesis and/or release of inflammatory pain mediators associated with tissue injury (Da Rocha *et al.*, 2011).

H. indicum was found to contain pyrrolizidine alkaloids, tannins, steroids and saponins which was in conformity to that reported by Burkill (1985). Contrary to the beneficial effects of these compounds in the leaves as analgesic, they may pose treat to human beings and animals that may use the leaves as a delicacy or medicinal. The hepatic injury associated with the administration of the HIE^A in this study may be due to the presence of compounds such as pyrrolizidine alkaloids. Indeed pyrrolizidine alkaloids have been implicated in liver damage, a form of hepatic-veno occlusive disease, (Klaassen, 2001). In Afghanistan, there was an epidemic of hepatic-veno occlusive disease from consumption of a wheat crop contaminated with seeds of a species of *Heliotropium* (Tandon *et al.*, 1978), the clinical signs associated with the liver damage resemble those of cirrhosis and some hepatic tumors and may be mistaken for those conditions (Mcdermott and Ridker, 1990). The clinical condition had been described as a form of Budd-Chiari Syndrome with portal hypertension and obliteration of small hepatic veins (Ridker *et al.*, 1985). Damage to hepatocytes has been proposed to be due to the formation of pyrrole metabolites from Pyrrolizidine alkaloids by liver microsomal oxidation, with cross linking of DNA strands by the pyrrole metabolites (Carballo *et al.*, 1992). Pyrrolizidine alkaloids produce necrosis or inhibition of mitosis depending on the dose but independent of the route of administration (Bull *et al.*, 1968). The diffused alveolar haemorrhage and extensive oedema with rupture of inter alveolar septae observed in the lungs, vascular congestion in the glomeruli with patchy focal chronic inflammation in the lungs as well as diffused single cell necrosis with mild diffused chronic

inflammation in the heart underscores the need to exercise caution when using *H. indicum* in the treatment of diseases.

CONCLUSION

Aqueous and ethanolic extracts of *H. indicum* exhibited analgesic properties in the neurogenic and inflammatory phases of the formalin test providing scientific evidence to the use of the plant as analgesic. The aqueous extract was however toxic in animals warranting the need to exercise caution when using the plant for medicinal purposes

ACKNOWLEDGMENT

The Authors wish to express their gratitude to Mr. Thomas Ansa of the Department of Pharmacology, KNUST and Mr. Adator K. Brown of the Department of Theoretical and Applied Biology, College of Sciences, KNUST for their technical assistance.

REFERENCES

- Ainslie, J.R., 1937. A List of Plants Used in Native Medicine in Nigeria. Imperial Forestry Institute, Oxford, pp: 109.
- Baig, M.S., S.M. Humail, S.I. Zaidi, S. Noor, S. Bano, S. Rehman and A. Fawwad, 2009. The efficacy of disease modifying anti-rheumatic drugs in rheumatoid arthritis in local patients of Karachi. Pak. J. Biol. Sci., 12: 339-345.
- Breivik, H., P.C. Borchgrevink, S.M. Allen, L.A. Rosseland and L. Romundstad *et al.*, 2008. Assessment of pain. Br. J. Anaesth., 101: 17-24.
- Bull, L.B., C.C.J. Culvenor and A.T. Dick, 1968. The Pyrrolizidine Alkaloids: Their Chemistry, Pathogenicity and Other Biological Properties. North-Holland Publishing Company, Amsterdam.
- Burkill, H.M., 1985. The Useful Plants of West Africa. 2nd Edn., The Royal Botanical Gardens, Ithaka Harbors Incorporation, Kew, UK., ISBN-10: 094764301X, Pages: 976.
- Burkill, I.H., 1935. A Dictionary of Economic Products of Malay Peninsula. Vol. 2, Crown Agents for Colonies, London, pp: 726.
- Carballo, M., M.D. Mudry, I.B. Larripa, Y.E. Villam and M. d'Aquino, 1992. Gentoxic action of an aqueous extract of *Heliotropium curassavicum* var. *argentinum*. Mutat. Res., 279: 245-253.
- Dalziel, J.M., 1937. The Useful Plants of West Tropical Africa. Crown Agents for the Colonies, London, pp: 462-463.

- Da Rocha, C.Q., F.C. Vilela, G.P. Cavalcante, F.V. Santa-Cecilia, L. Santos-e-Silva, M.H. dos Santos and A. Giusti-Paiva, 2011. Anti-inflammatory and antinociceptive effects of *Arrabidaea brachypoda* (DC.) bureau roots. J. Ethnopharmacol., 133: 396-401.
- Elisabetsky, E., T.A. Amodor, R.R. Albuquerque, D.S. Nunes and A.C.T. Carvalho, 1995. Analgesic activity *Psychotria colorata* (wild. ex R and S). Muell arg. alkaloids. J. Ethnopharmacol., 48: 77-83.
- Ellis, A., N. Benson, I. Machin and L. Corradini, 1998. The rat formalin test: Can it predict neuropathic pain treatments? Proceedings of the Measuring Behavior (Maastricht, The Netherlands), August 26-29, 2008, UK, pp: 324-325.
- Harborne, J.B., 1998. Phytochemical Methods. 3rd Edn., Chapman and Hall, London, ISBN: 0-412-57260-5, Pages: 302.
- Ibironke, G.F., E.A. Omokhagbo and K.O. Ajeigbe, 2009. Comprehensive evaluation of malnutrition effect on pain threshold in albino rats. Asian J. Clin. Nutr., 1: 88-96.
- Iroanya, O., J. Okpuzor and H. Mbagwu, 2010. Antinociceptive and anti-phlogistic actions of a polyherbal decoction. Int. J. Pharmacol., 6: 31-36.
- Irvine, F.R., 1961. Woody Plants of Ghana. 1st Edn., Oxford University Press, London.
- Khaksarian, M., M. Javan, A. Sonboli and F. Motamedi, 2005. The effects of peripheral and central administration of *Hypericum perforatum* L. on chronic and acute pain in male rats. Pak. J. Biol. Sci., 8: 949-953.
- Khoshraftar, E., H.M. Anvari, H.K. Assadi, A.S. Abdulmir and F. Abu Bakar, 2011. Comparative study on the effectiveness of acetaminophen and diclofenac pretreatment in the relief of acute pain after out-patient surgery. Eur. J. Dentistry Med., 3: 23-27.
- Klaassen, C.D., 2001. Casarett and Doull's Toxicology. The Basic Science of Poisons. 6th Edn., McGraw-Hill, New York, ISBN-13: 978-0071347211, Pages: 1275.
- Kugelman, M., W.C. Liu, M., Axelrod, T.J. McBride and K.V. Rao, 1976. Indicine-N-oxide: The antitumor principle of *Heliotropium indicum*. Lloydia, 39: 125-128.
- Malmberg, A.B. and T.L. Yaksh, 1992. Anti-nociceptive actions of spinal non-steroidal anti-inflammatory agents on the formalin test in the rat. J. Pharmacol. Exp. Ther., 263: 136-146.
- Mcdermott, W.V. and P.M. Ridker, 1990. The budd-chiarri syndrome and hepatic veno-occlusive disease. recognition and treatment. Arch Surg., 125: 525-527.
- Mohajer, M., P. Sarkhail, N. Hajarolasvadi, M.J. Zamani, R. Khorasani, A. Shafiee, G. Amin and M. Abdollahi, 2006. Antiinflammatory and analgesic effects of *Phlomis lanceolata* boiss. and hohen. extracts and examination of their components. Int. J. Pharmacol., 2: 50-54.
- Mokhtari, M., M. Shariati and L. Rezaeian, 2007. Effects of L-name on antinociceptive induced by morphine in formalin test. AJAVA., 2: 15-20.
- Okokon, J.E., B.S. Antia and E. Umoh, 2008. Analgesic and anti-inflammatory effects of ethanolic root extract of *Hippocratea africana*. Int. J. Pharmacol., 4: 51-55.
- Oliver, B., 1960. Medicinal Plants in Nigeria. University of Ibadan Press, Ibadan, Nigeria.
- Pass, D.A., G.G. Hogg, R.G. Russell, J.A. Edgar and I.M.T.L. Rikard-Bell, 1979. Poisoning of chickens and ducks by pyrrolizidine alkaloids of *Heliotropium europaeum*. Aust. Vet. J., 55: 284-288.
- Quisumbing, E., 1951. Medicinal plants of the Philippines. Department of Agriculture and Natural Resources. Manila: Bureau of Printing, pp: 298-351.
- Ridker, P.M., S. Okhuma, W.V. McDermott, C. Trey and R.J. Huxtable, 1985. Hepatic veno-occlusive disease associated with the consumption of pyrrolizidine containing dietary supplements. Gastroenterology, 88: 1050-1054.
- Rios, J.L., M.C. Recio, J.M. Escandell and I. Andujar, 2009. Inhibition of transcription factors by plant-derived compounds and their implications in inflammation and cancer. Curr. Pharm. Des., 15: 1212-1237.
- Ronald, D. and R.D. Miller, 2005. Miller's Anesthesia. Elsevier Churchill Livingstone, Philadelphia.
- Schim, J.D. and P. Stang, 2004. Overview of pain management. Pain Pract., 4: S4-S18.
- Sofowora, A., 1993. Screening Plants for Bioactive Agents: Medicinal Plants and Traditional Medicine in Africa. 2nd Edn., Spectrum Books Ltd., Sunshine House, Ibadan, Nigeria, ISBN-13: 978-0471103677, pp: 134-156.
- Tandon, H.D., B.N. Tandon and A.R. Mattocks, 1978. An epidemic of veno-occlusive disease of the liver in Afganistan. Pathologic features. Am. J. Gastroenterol., 70: 607-613.
- Tjolsen, A., O. Berge, S. Hunskaar, J.H. Rosland and K. Hole, 1992. The formalin test an evaluation of the method. Pain, 51: 5-17.
- Trease, G.E. and W.C. Evans, 1989. A Textbook of Pharmacognosy. 13th Edn., Bailliere Tindall Ltd., London, ISBN: 0702013617.
- Turk, D.C. and R.H. Dworkin, 2004. What should be the core outcomes in chronic pain clinical trials? Arthritis Res. Ther., 6: 151-154.

- Woode, E., E. Boakye-Gyasi, G.K. Ainooson, C. Ansah and M. Duwiejua, 2009a. Anti-nociceptive effects and the mechanism of *Palisota hirsuta* K. Schum. Leaf extract in murine models. *Int. J. Pharmacol.*, 5: 101-113.
- Woode, E., R.A. Poku, G.K. Ainooson, E. Boakye-Gyasi, W.K.M. Abotsi, T.L. Mensah and A.K. Amoh-Barimah, 2009b. An evaluation of the anti-inflammatory, antipyretic and antinociceptive effects of *Ficus exasperata* (Vahl) leaf extract. *J. Pharmacol. Toxicol.*, 4: 138-151.
- Yaksh, T.L., G. Ozaki, D. McCumber, M. Rathbun, C. Svensson, S. Malkmus and M.C. Yaksh, 2001. An Automated flinch detecting system for use in the formalin nociceptive bioassay. *J. Applied Physiol.*, 90: 2386-2402.
- Zakaria, Z.A., R.N.S.R. Mohd Nor, M.R. Sulaiman, Z.D.F.A. Ghani, G.H. Kumar and C.A. Fatimah, 2006. Antinociceptive and anti-inflammatory properties of *Melastoma malabathricum* leaves chloroform extract in experimental animals. *J. Pharmacol. Toxicol.*, 1: 337-345.