

See discussions, stats, and author profiles for this publication at: <https://www.researchgate.net/publication/257746799>

Protective effects of vitamin C against propanil-induced hepatotoxicity in wistar rats

Article in *Asian Pacific Journal of Tropical Disease* · December 2012

DOI: 10.1016/S2222-1808(12)60154-6

CITATIONS

11

READS

127

6 authors, including:



Chiagoziem Otuechere

Redeemer's University

46 PUBLICATIONS 261 CITATIONS

SEE PROFILE



Sunny Abarikwu

Federal University of Minas Gerais

63 PUBLICATIONS 1,018 CITATIONS

SEE PROFILE



Martins Ekor

University of Cape Coast

53 PUBLICATIONS 1,723 CITATIONS

SEE PROFILE



Olatunde Farombi

University of Ibadan

178 PUBLICATIONS 7,303 CITATIONS

SEE PROFILE

Some of the authors of this publication are also working on these related projects:



Carotid artery occlusion to simulate stroke in rats [View project](#)




Nigerian Drosophila Research Community [View project](#)



Contents lists available at ScienceDirect

Asian Pacific Journal of Tropical Disease

journal homepage: www.elsevier.com/locate/apjtd

Document heading

Protective effects of vitamin C against propanil-induced hepatotoxicity in wistar rats

Chiagoziem Anariochi Otuechere^{1*}, Sunny Okechukwu Abarikwu¹, Mayodele Ayooluwa Rufai¹, Annemaria Ebihnomon Ohiozoje¹, Ekor Martins¹, Ebenezer Olatunde Farombi²

¹Division of Biochemistry, Department of Chemical Sciences, Redeemer's University, Mowe, Ogun State, Nigeria

²Drug Metabolism and Toxicology Research Laboratories, Department of Biochemistry, College of Medicine, University of Ibadan, Nigeria

ARTICLE INFO

Article history:

Received 25 June 2012

Received in revised form 5 July 2012

Accepted 17 October 2012

Available online 28 October 2012

Keywords:

Propanil

Hepatotoxicity

Vitamin C

Lipid peroxidation

Antioxidants

Wistar rat

Hepatoprotection

ABSTRACT

Objective: To investigate the hepatoprotective effects of Vitamin C in propanil intoxicated Wistar rats. **Methods:** Twenty-four adult male rats were divided into four equal groups of six each: control; 100mg propanil/kg; 100mg vitamin C/kg; propanil (100mg/kg) plus vitamin C (100mg/kg). Treatment was via oral route and was administered once daily for 7 days. Animals were orally treated once daily for 7 days. The effect of propanil on liver lipid peroxidation, antioxidant enzymes and biochemical parameters as well as the possible attenuation of its toxicity by vitamin C was studied. **Results:** Compared to the control group, propanil treatment significantly increased serum total cholesterol, alkaline phosphatase (ALP), alanine aminotransferase (ALT), aspartate aminotransferase levels (AST), and significantly lowered triglyceride (TG), high density lipoprotein cholesterol (HDL) and total protein (TP) levels. Results obtained furthermore showed that propanil significantly ($P < 0.05$) induced malondialdehyde (MDA) levels while the activities of glutathione-S-transferase (GST), superoxide dismutase (SOD) and catalase (CAT) were decreased in the liver tissues. However, co-administration of propanil with vitamin C ameliorated the harmful effects of propanil in most of the tested parameters. Liver histological studies revealed changes in liver tissues and the protective role of vitamin C. **Conclusion:** The present study suggests that Vitamin C could be an important dietary component based on its ability to attenuate propanil induced hepatotoxicity.

1. Introduction

Propanil (dichloropropanilide), a highly selective post-emergent contact herbicide, is one of the most extensively used herbicides for rice production worldwide and is ranked within the top twenty pesticides used in agriculture. The propanil use in Africa is considerable, but a large percentage of the rice crops from Asia, North and South America are treated with it [1, 2].

Propanil exposure has been associated with toxicity in humans and other animals. In a study, commercial formulations containing propanil herbicides at rice field

concentrations were shown to cause changes in toxicology and metabolic parameters of teleost fish, *Leporinus obtusidens*. [3]. It has been reported that propanil toxicity, mediated by its enzymatic conversion to 3,4, dichloroaniline was toxic to rats and the target organs were the kidney, liver, urinary bladder, and the reproductive system [4]. Also, Rankin, et al [5] demonstrated that propanil has the potential to induce cytotoxicity and nephrotoxicity in vitro. Environmental exposure to pesticides may affect the human health by increasing the incidence of certain disorders at the level of the general population [6]. The toxic effects of organic compounds are clearly mediated by reactive oxygen species (ROS) which can react with biological molecules and initiate oxidative damage including protein oxidation, reduced glutathione (GSH) depletion and lipid peroxidation (LPO). LPO, variations in levels of GSH and antioxidant enzymes such as superoxide dismutase (SOD), catalase (CAT), glutathione peroxidase

*Corresponding author: Otuechere, Chiagoziem Anariochi. Present Address: Biochemistry Unit, Department of Chemical Sciences, and Redeemer's University Km 46, Lagos-Ibadan Expressway, Redemption City, Mowe, Ogun State, Nigeria
Tel: +234-802 388 7060;
E-mail addresses: goziemo12@yahoo.com, otuechere@run.edu.ng

(GPX) have been proposed as indicators of pollutant mediated oxidative stress [7,8].

The liver is the main organ of detoxification where most of the metabolisms take place. Due to its role in the transformation of environmental xenobiotics, the liver is at great risk of injury, when high intracellular concentrations of pollutant can be reached. [9].

To overcome the oxidative stress, several reports suggest that natural antioxidants constitute efficient treatment of toxicity induced by xenobiotics. Non- enzymatic antioxidants such as vitamins E and C, and polyphenolic compounds represent some of these natural antioxidants. Studies have shown that Vitamin C, a free radical scavenger in extracellular fluids, could protect biomembranes from peroxidative damage induced by pesticides [10, 11].

Thus, the present study was carried out to determine the effect of acute 7 days exposure to propanil on the hepatic integrity of rats. The possible ameliorating effect of Vitamin C against propanil toxicity was also investigated.

2. Materials and methods

2.1 Chemicals

Commercial herbicide, Propanil was purchased from Harvest Field Industries Limited, Lagos State, Nigeria. Other reagents were of analytical grade and of the purest quality available.

2.2 Animals

Albino rats, 5–6 weeks old, of the Wistar strain, weighing between 150g and 200g were purchased from Covenant Farm animal house located at Ibadan, Oyo State, Nigeria. The animals were kept in well-ventilated cages at room temperature and under controlled light cycles at the Redeemer's University Animal House facility, Mowe, Ogun State, Nigeria. They were maintained on normal laboratory chow and water ad libitum. The experiment was approved by the Animal Ethics Committee of the Redeemer's University.

2.3 Experimental design

Twenty-four (24) albino rats were randomly distributed into four groups of six animals each and were allowed free access to feed and water for a week before the commencement of the experiment, which lasted for 7 days. The first group served as the control and animals received diluted dimethylsulfoxide (DMSO). The second group animals were given Vitamin C (100mg/kg) while the third group was treated with propanil (100mg/kg) dissolved in DMSO and vitamin C (100mg/kg). Finally, the fourth group received propanil alone (100mg/kg).

2.4 Sample collection

Rats were sacrificed after the last dose of administration and an overnight fast. Heart, kidney, and liver samples were

quickly removed and washed in ice-cold 1.15% KCl solution, dried and weighed. The liver samples were homogenized in 4 volumes of 5 mM phosphate buffer, pH 7.4 and centrifuged at 4000g for 25 minutes to obtain a purified homogenate. The samples were stored in the freezer until use. All procedures were carried out at a temperature 0–40C. Blood was collected from the inferior vena cava of heart of the animals into plain universal tubes and was allowed to stand for 1 hour. Serum was prepared by centrifugation at 4000g for 10 min. in a Centrifuge (Heraeus Labofuge 300 model). The clear supernatant was used for the estimation of the serum enzymes and lipid profile parameters.

2.5 Biochemical analysis

Liver protein level was determined to the method of Biuret reaction as described by Gornall et al. [12], using bovine serum albumin as standard. Lipid peroxidation was determined by measuring the formation of thiobarbituric acid reactive substances (TBARS) according to the method of Varshney and Kale [13]. Glutathione-S-transferase (GST) activity was determined according to Habig et al [14]. The method of Beutler et al. [15] was followed in estimating the level of reduced glutathione. The level of superoxide dismutase (SOD) activity was determined by the method of Misra and Fridovich [16]. Catalase activity was determined according to the method of Singha [17]. Alkaline Phosphatase (ALP), Aspartate Amino Transferase (AST), Alanine Amino Transferase (ALT), Total Cholesterol, Triglyceride and High Density Lipoprotein-Cholesterol were measured by spectrophotometry in serum using Randox commercial kits.

2.6 Histopathology

Livers from rats of all the groups were fixed in 10% formaldehyde, dehydrated in graded alcohol and embedded in paraffin. Fine sections were obtained, mounted on glass slides and counter-stained with hematoxylin and eosin for light microscopic analyses. The slides were coded and were examined by a histopathologist who was blinded to the treatment groups. All sections were evaluated for the degree of hemorrhage, vacuolar degeneration and congestion, and necrosis.

2.7 Statistical Analysis

All values have been expressed as mean \pm standard deviation (SD) of six observations. Data were analyzed using one way analysis of variance (ANOVA) followed by Dunnett's post-test for analysis of biochemical data. Statistical analyses were performed using SPSS statistical version 8 software package. Values were considered statistically significant at $P < 0.05$.

3. Results

Biochemical endpoints were investigated to assess the effects

of 7 days acute propanil exposure on hepatic function and the lipid profile. The protective effect of vitamin C was also studied (Table 1). Total protein, AST, ALT and ALP are indicators of hepatic function. AST, ALT and ALP levels were higher in propanil-treated rats by 127%, 66% and 318% respectively, as compared to the control rats. Conversely, there was a 23% reduction in total protein levels in propanil exposed rats when compared with the control group. Furthermore, the vitamin C plus propanil group also had significantly lower AST, ALT and ALP levels than the propanil-treated group but did not differ from the propanil-fed rats in terms of total protein levels ($P < 0.05$).

Results for the lipid profile parameters are also presented in Table 1. Propanil administration alone and in combination with vitamin C resulted in significant decrease ($P < 0.05$) in triglyceride (TG) and high density lipoprotein cholesterol levels when compared with the control group; however, total cholesterol (TC) values were increased. Comparison between the vitamin C plus propanil-treated rats and propanil-treated rats did not reveal any significant difference in the tested lipid profiles.

Table 1

Effect of acute exposure to propanil on the absolute organ weights of wistar rats

Organs	Control	Vitamin C	Propanil	Vitamin C + Propanil
Liver (g)	2.81 ± 0.04	3.35 ± 0.05	3.07 ± 0.04*	3.38 ± 0.36
Kidney (g)	0.64 ± 0.10	0.62 ± 0.07	0.60 ± 0.02*	0.64 ± 0.06*†
Heart (g)	0.35 ± 0.04	0.36 ± 0.05	0.36 ± 0.004*	0.33 ± 0.05†

Values are mean ± SD of six rats in each group. Significance at $P < 0.05$

* Comparison against control

† Comparison against propanil group

Table 2

Effect of acute exposure to Propanil on the biochemical parameters of Wistar rats

Parameters	Control	Vitamin C	Propanil	Vitamin C + Propanil
Total protein (g/dl)	3.25 ± 0.03	3.20 ± 0.03	2.50 ± 0.01*	3.10 ± 0.01
AST (U/L)	15.0 ± 1.03	18.7 ± 2.51	34.3 ± 0.02*	19.3 ± 1.06*†
ALT (U/L)	18.4 ± 1.07	19.5 ± 1.50	30.5 ± 1.82*	20.6 ± 0.91†
ALP (U/L)	4.83 ± 0.98	4.15 ± 0.11	20.2 ± 3.57*	12.8 ± 0.21*†
TC (mg/dl)	3.30 ± 0.18	4.23 ± 0.21	6.60 ± 1.57*	7.80 ± 1.51*
TG (mg/dl)	51.1 ± 9.20	43.7 ± 0.38*	44.2 ± 3.52*	42.8 ± 0.42*
HDLc (mg/dl)	2.59 ± 0.10	1.15 ± 0.31	0.94 ± 0.07*	0.78 ± 0.02*

Values are mean ± SD of six rats in each group. Significance at $P < 0.05$

* Comparison against control

† Comparison against Propanil group

Table 3

Effect of acute exposure to Propanil on the antioxidant defense systems and lipid peroxidation levels in liver of rats

Parameters	Control	Vitamin C	Propanil	Vitamin C + Propanil
CAT (μ mol/min/g)	8.80 ± 0.03	25.0 ± 0.06*	7.0 ± 0.55	11.0 ± 0.46
GST (μ mol/min/g tissue)	32.2 ± 0.02	35.9 ± 0.05	20.3 ± 0.03*	27.0 ± 2.16*†
GSH (mg/100mg tissue)	1.60 ± 0.02	1.45 ± 1.50	0.85 ± 0.01*	0.93 ± 0.02*
SOD (unit/g tissue)	23.0 ± 0.03	22.1 ± 0.03	16.2 ± 0.01*	17.8 ± 0.03*
MDA (μ mol/mg protein)	11.2 ± 0.13	8.1 ± 0.07	22.4 ± 0.18*	18.8 ± 0.22*†

Values are mean ± SD of six rats in each group. Significance at $P < 0.05$

* Comparison against control

† Comparison against Propanil group

In the liver of propanil treated rats, the levels of malondialdehyde were found to be elevated but the activities of Catalase (CAT), glutathione-S-transferase (GST), reduced glutathione (GSH) and superoxide dismutase (SOD) were decreased when compared to control animals. On the other hand, vitamin C plus propanil administration caused a slight decrease ($P < 0.05$) in MDA levels and an increase in the activities of GST, SOD and CAT compared to the control group (Table 2). When the vitamin C treated rats were compared to the propanil group, they did not differ significantly in terms of CAT, GSH and SOD values but the MDA and GST values were significantly different ($P < 0.05$).

3.1 Histopathology

Photomicrographs of the liver indicated that the livers of the control and vitamin C treated rats exhibited normal arrangement of the cells, though blood clots within the portal vein was observed in the later (Figure 1 A and B). On the other hand, hepatocytes in the propanil/and or vitamin C groups exhibited some histopathological changes: the livers of propanil-treated

rats showed focal hepatocellular necrosis, disruption of hepatic plates, vacuolar degeneration and infiltration of lymphocytes at foci of necrosis (Figure C1 & C2). Furthermore, the livers of vitamin C plus Propanil treated animals exhibited periportal aggregation of inflammatory cells but did not display the vacuolar degeneration and necrosis observed in the pesticide treated rats.

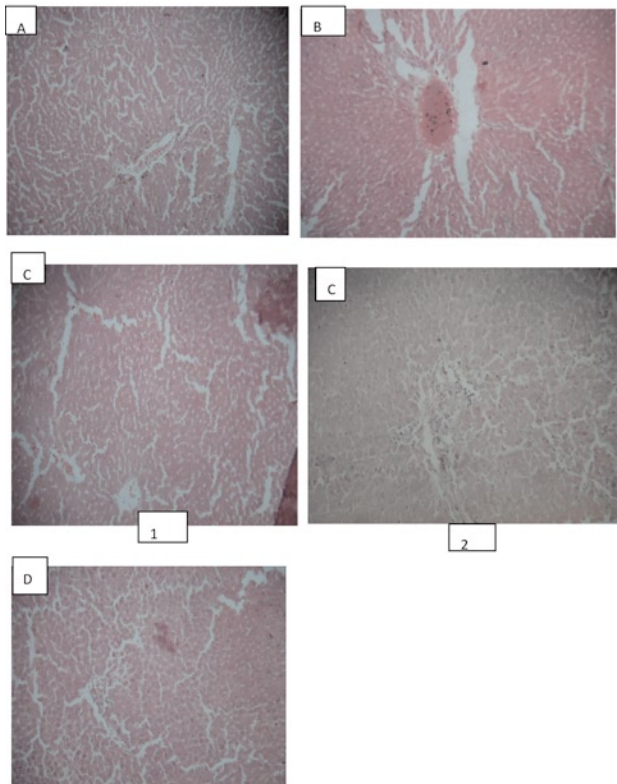


Figure 1: Photomicrograph of rat liver section(X 100). (A) Control rat liver section.(B) Vitamin C treated rat showing eosinophilic material in the central vein .(C) Propanil–treated rats showing (1) wide spread hepatocyte degeneration and necrosis (2) moderate disruption of hepatic plates and infiltration of lymphocytes.(D)Liver sections of propanil plus vitamin–treated rats showing mild periportal aggregates of inflammatory cells

4. Discussion

Even though the World Health Organization recognized propanil as slightly hazardous in terms of human risk [18] , earlier studies with propanil have demonstrated its capability to cause several toxic manifestations in humans and animals. [2, 3] . Previously, studying the toxic effects of propanil in rats, it was determined that when administered intraperitoneally at a dose of 50 mg/kg body weight, propanil caused multi–organ damage by increasing lipid peroxidation of the tissues but not necessarily an alteration on the lipid profiles [19].

It is accepted that an increase in MDA levels reflect enhanced oxidative damage to the cell membranes. The present study suggests that increased lipid peroxidation contribute to propanil–induced toxicity by the generation of covalent adducts between proteins and the carbonyl groups of the malondialdehyde [20]. Destroyed tissues undergo lipid

peroxidation faster than healthy ones; therefore the effect of propanil on tissue susceptibility could be due to the ability of the herbicide to cause tissue damage [9]. In our study, following exposure to propanil, the MDA levels increased by approx 17% in the liver of rats thereby supporting the hypothesis that lipid peroxidation may be one of the molecular mechanisms involved in herbicide–induced toxicity.

The primary role of vitamin C is to neutralize free radicals, since ascorbic acid is water soluble, it can work both inside and outside the cells to combat free radical damage. The free radicals will seek out an electron to regain their stability and vitamin C being an excellent source of electrons can donate electrons to free radicals such as hydroxyl and superoxide radicals and quench their reactivity [21].

Gultekin *et al* [22] have shown that pretreatment of rats with melatonin or a combination of vitamins E and C with the repeated doses — one per day — for six days consecutively prior to the administration of chlorpyrifos–ethyl reduced lipid peroxidation. Also, the results of another previous study showed that a 2, 4–dichlorophenoxyacetic acid based herbicide also induced lipid peroxidation [23]. The present study showed that vitamin C slightly reduced MDA levels in combination with propanil. These results indicate the likely beneficial effects of vitamin C to over–come oxygen–dependant cytotoxicity in animals. Several of soluble enzymes of blood serum have been considered as indicators of hepatic dysfunction and damage. AST, ALT and ALP levels were higher in propanil–treated rats by 127%, 66% and 318% respectively, as compared to the serum levels of control rats. The increased cytolysis expressed by the higher serum levels of AST, ALT and ALP in propanil–treated rats suggest that the enhanced liver lipid peroxidation is associated to a damage to this tissue. In addition, Rahman *et al* [24] suggested that the increase in the activities of ALP in plasma might be due to the increased permeability of plasma membrane or cellular necrosis, and this showed the stress condition of the treated animals. The presence of Vitamin C with propanil decreased the induction of AST and ALT and maintained the levels of these enzymes to the normal values. This is consistent with the damage to the liver of propanil–treated rats as depicted by light microscopy. However, vitamin C treatment was unable to reverse the elevated ALP marker enzyme. According to a study by Kalendar and co workers [11] antioxidants may show protective effects on some biochemical indices but not on some parameters.

It has also been suggested that exposure to environmental pollutants caused changes in lipids profile [25]. The increase in plasma lipids due to propanil administration indicates a loss of membrane integrity which is corroborated by the significant effect on the various membrane–bound enzymes in terms of increased activities of serum AST, ALT, ALP.

Triglycerides are the main storage forms of fatty acids. Generally, herbicides cause increase of total cholesterol levels, however, in our study, the TC levels were decreased. This is in agreement with an earlier report that some pesticides

caused a decrease in TC levels possibly as a result of hepatic damage which makes the liver unable to synthesize enough cholesterol from acetate [19]. Alternatively, the low serum cholesterol levels could be directly ascribed to an oxidant effect of propanil on circulating cholesterol, in accordance with the suggestion that cholesterol levels are directly correlated to the extent of its peroxidation into the blood [26]. There was a significant decrease in the TC levels and a significant increase in the HDLC levels when Vitamin C was administered alone. The present results agree with previous reports as documented by Charterjea and Shinde [27] which observed the reduction in serum cholesterol in experimental animals administered Vitamin C. A plausible explanation for the observed effect on serum lipids may be due to the activation of the enzyme γ - hydroxylase by vitamin C which enhances the conversion of plasma cholesterol into bile acid hence resulting in a decrease in serum levels of cholesterol.

The reduction in total protein in rats exposed to environmental pollutants could be attributed to low globulin concentration following acute pesticide exposure [28]. Additionally, the protein depression may be due to reduced protein synthesis or increased proteolytic activity or degradation. The observed decrease in proteins could be also attributed in part to the damaging effect of propanil on liver cells as confirmed by the increase in the activities of plasma AST, ALT, ALP [29].

The present data showed that vitamin C afforded about 76% restoration in the overall protein turnover of animals treated with propanil and this is in consonance with previous studies that Vitamin C resulted in an increase in total protein concentrations in chlorpyrifos and gasoline vapour induced toxicities in rats [28, 29].

SOD, CAT and GST provide the cellular defence against the intermediates of dioxygen reduction (superoxide radical, hydrogen peroxide and hydroxyl radical). SOD converts superoxide radicals into hydrogen peroxide, which in turn has to be removed by CAT. On the other hand, GST is a group of multifunctional proteins encoded by a multigene family. They perform functions ranging from catalyzing the detoxification of electrophilic species via a spontaneous enzyme catalyzed conjugation reaction to protect the cells against peroxidative damage [30].

Glutathione has multiple functions ranging from antioxidant defense to modulation of immune function and many conditions are related to low glutathione levels. Glutathione concentration has been found to be decreased in chemically induced toxicity. The development of diseases may be affected by depleting GSH levels [31]. Depletion of GSH results in the inhibition of GPx, which makes the cells more vulnerable to oxidative stress. GSH is also a very important constituent of detoxification pathways.

There was a significant decline in the activities of SOD, CAT and GST after propanil administration, which may be due to oxidative stress. CAT protects SOD against inactivation by hydrogen peroxide. Reciprocally SOD protects CAT from

inhibition by superoxide radicals [32]. Therefore the balance of this enzyme system is crucial to keep the steady state concentration of the oxygen radicals low. In the present study, supplementation with vitamin C increased the activity of these enzymes. This may be due to scavenging of superoxide radical and peroxy radicals by Vitamin C, since it is part of the redox buffer system. Low levels of GSH were observed during increase in oxidative stress. These observations support our findings where we have observed a decline in GSH levels with an increase in oxidative stress, as evidenced by increased LPO. Administration of vitamin C helps to overcome the oxidative stress caused by propanil, by increasing the GSH status which in turn exhibits increased free radical scavenging property. The reduced activity of GST observed in our study may be partly due to the lack of its substrate (GSH) and also because of oxidative modification of its protein structure.

Uzunhisarcikli and Kalender (2011) [10] reported that an organophosphate insecticide, methyl parathion, caused swelling of mitochondria in rat hepatocytes. In this study, we observed that propanil-treatment led to infiltration of mononuclear cells, focal hepatocellular necrosis, and widespread vacuolar degeneration. These changes could be consequences of an increase in free radical species formation in the hepatocytes. But milder histopathological changes were observed in the Vitamin C treated groups.

Overall, our findings demonstrate that the exposure of animals to propanil is capable of inducing free radicals, marked hazardous alterations in some enzymatic activities and some biochemical parameters. It also showed that, Vitamin C reduced the levels of free radicals and increased the activities of antioxidant enzymes and the content of GSH. Therefore, vitamin C administration might be beneficial in attenuating the hepatic oxidative stress induced by propanil but this protection may not be absolute.

Conflict of interest statement

We declare that we have no conflict of interest.

Acknowledgement

The authors wish to thank the Department of Chemical Sciences, Redeemer's University, Mowe, Ogun State, Nigeria for assistance for lab space, chemicals and access to equipment.

References

- [1] Norsworthy JK, Bangarwa SK, Scott RC, Still J, Griffith GM. Use of propanil and quinclorac tank mixtures for broadleaf weed control on rice (*Oryza sativa*) leaves. *Crop Protection* 2010; **29**: 255–259.
- [2] Darren R, Renate H, Nick B, Andrew D, Mohamed F, Michael E, Peter E. Clinical outcomes and kinetics of propanil following acute

- self-poisoning: a prospective case series, *BMC Clin Pharmacol* 2009; **9**: 3 doi:10.1186/1472-6904-9-3.
- [3] Moraes BS, Loro VL, Pretto A, Braga da Fonseca M, Menezes C, Marchesan E, et al. Toxicological and metabolic parameters of the teleost fish (*Leporinus obtusidens*) in response to commercial herbicides containing clomazone and propanil. *Pesticide Biochemistry and Physiology* 2009; **95**: 57–62.
- [4] Zhang B, Sen L. Effects of 3, 4-Dichloroaniline on Testicle Enzymes as Biological Markers in Rats. *Biomedical and Environmental Sciences* 2009; **22**: 40–43.
- [5] Rankin GO, Racine C, Sweeney A, Krainie A, Dianne KA, Barnett JB. In vitro nephrotoxicity induced by propanil. *Environ Toxicol* 2008; **23**: 435–442.
- [6] Tesifón P, Mar R, Hernández AF, Alarcón R. Association between environmental exposure to pesticides and neurodegenerative diseases. *Environmental Chemicals and Neurotoxicity* 2011; **256**(3): 379–385.
- [7] Yuanxiang J, Linggang W, Meili R, Jingwen L, Yuefeng Yang, Cheng Zhou, et al. Cypermethrin exposure during puberty induces oxidative stress and endocrine disruption in male mice *Chemosphere* 2011; **84**: 124–130.
- [8] Mitra E, Ghosh AK, Ghosh D, Mukherjee D, Chattopadhyay A, Dutta S, et al. Protective effect of aqueous Curry leaf (*Murraya koenigii*) extract against cadmium-induced oxidative stress in rat heart. *Food and Chemical Toxicology* 2012; **50**: 1340–1353.
- [9] Sefi M, Bouaziz H, Soudani N, Boudawara T, Zeghal N. Fenthion induced-oxidative stress in the liver of adult rats and their progeny: Alleviation by *Artemisia campestris*. *Pesticide Biochemistry and Physiology* 2011; **101**: 71–79.
- [10] Uzunhisarcikli M, Kalender Y. Protective effects of vitamins C and E against hepatotoxicity induced by methyl parathion in rats. *Ecotoxicology and Environmental Safety* 2011; **74**: 2112–2118.
- [11] Kalender S, Uzun FG, Durak D, Demir D, Kalender Y. Malathion-induced hepatotoxicity in rats: The effects of vitamins C and E. *Food and Chemical Toxicology* 2010; **48**: 633–638.
- [12] Cornall AG, Bardawill CJ, David MM. Determination of Serum Proteins by means of the Biuret Reaction. *J Biol Chem* 1949; **177**: 751–766.
- [13] Varshney R, Kale RK. Effect of calmodulin antagonist on radiation induced lipid peroxidation in microsomes. *Int J Rad Biol* 1990; **58**: 733–743.
- [14] Habig WH, Pabst MJ, Jacoby WB. Glutathione-S-transferases: The first enzymatic step in mercapturic acid formation. *J Biol Chem* 1974; **249**: 7130–7139.
- [15] Beutler E, Duron O, Kelly BM. Improved method for the determination of blood glutathione. *J Lab Clin Med* 1963; **61**: 882–888.
- [16] Misra HP, Fridovich I. The univalent reduction of oxygen by reduced flavins and quinines. *J Biol Chem* 1972; **247**: 188–192.
- [17] Singha AK. Colorimetric assay of catalase. *Anal Biochem* 1972; **47**: 389–394.
- [18] World Health Organization. WHO Recommended Classification of Pesticides by Hazard and Guidelines to Classification, World Health Organization, Geneva 2004a.
- [19] Santillo M, Rippa C, Morte R, Villani G, Santangelo F, Staiano N, et al. Enhancement of tissue lipoperoxidation in propanil-treated rats. *Toxicology Letters* 1995; **78**: 215–218.
- [20] Ojha A, Yaduvanshi SK, Srivastava N. Effect of combined exposure of commonly used organophosphate pesticides on lipid peroxidation and antioxidant enzymes in rat tissues. *Pesticide Biochemistry and Physiology* 2011; **99**: 148–156.
- [21] EL-Gendy KS, Aly NM, Mahmoud FH, Kenawy K, El-Sebae AK. The role of vitamin C as antioxidant in protection of oxidative stress induced by imidacloprid. *Food and Chemical Toxicology* 2010; **48**: 215–221.
- [22] Gultekin F, Delibas N, Yas_ar S, Kilnc I. In vivo changes in antioxidant systems and protective role of melatonin and a combination of vitamin C and vitamin E on oxidative damage in erythrocytes induced by chlorpyrifos-ethyl in rats. *Arch Toxicol* 2001; **75**: 88–96.
- [23] Tayeb W, Nakbi A, Trabelsi M, Attia N, Miled A, Hammami M. Hepatotoxicity induced by sub-acute exposure of rats to 2,4-Dichlorophenoxyacetic acid based herbicide “Désormone lourde”. *Journal of Hazardous Materials*, 2010; **180**: 225–233.
- [24] Rahman MF, Siddiqui MK, Jamil K. Acid and alkaline phosphatase activities in a novel phosphorothionate (RPR-11) treated male and female rats. Evidence of dose and time-dependent response. *Drug Chem Toxicol* 2000; **23**: 497–509.
- [25] Begum K, Rajini PS. Monocrotophos augments the early alterations in lipid profile and organ toxicity associated with experimental diabetes in rats. *Pesticide Biochemistry and Physiology* 2011; **99**: 33–38.
- [26] Dauqan EM, Abdullah A, Sani HA. Natural Antioxidants, Lipid Profile, Lipid Peroxidation, Antioxidant Enzymes of Different Vegetable Oils. *Advance Journal of Food Science and Technology* 2011; **3**(4): 308–316.
- [27] Chatterjea MN, Shinde R. Textbook of Medical Biochemistry; 5th ed AYPE; 2002. p. 154–157.
- [28] Ambali SF, Onukak C, Idris SB, Yaqub LS, Shittu M, Aliyu H, et al. Vitamin C attenuates short-term hematological and biochemical alterations induced by acute chlorpyrifos exposure in Wistar rats. *Journal of Medicine and Medical Sciences* 2010; **1**(10):465–477.
- [29] Uboh FE, Ebonga PE, Umoh IB. Comparative Hepatoprotective Effect of Vitamins A and E Against Gasoline Vapor Toxicity in Male and Female. *Gastroenterology Research* 2009; **2**(5):295–302.
- [30] Brandsch C, Schmidt T, Behn D, Weiße K, Mueller AS, Stangl GI. Glutathione deficiency down-regulates hepatic lipogenesis in rats *Lipids in Health and Disease* 2010, 9:50 doi:10.1186/1476-511X-9-50
- [31] Rezazadeh A, Yazdanparas R, Molaei M. Amelioration of diet-induced nonalcoholic steatohepatitis in rats by Mn-salen complexes via reduction of oxidative stress. *Journal of Biomedical Science* 2012; **19**:26 doi:10.1186/1423-0127-19-26.
- [32] Aly HA, Domènech O, Abdel-Naim AB. Aroclor 1254 impairs spermatogenesis and induces oxidative stress in rat testicular mitochondria. *Food and Chemical Toxicology* 2009; **47**(8): 1733–1738.