

See discussions, stats, and author profiles for this publication at: <https://www.researchgate.net/publication/234097247>

Asymptomatic incisional endometrioma presenting as abdominal wall mass: a case report

Article in *Nigerian journal of medicine: journal of the National Association of Resident Doctors of Nigeria* · January 2013

Source: PubMed

CITATIONS

0

READS

15

4 authors, including:



Ganiyu A Rahman

University of Ilorin

94 PUBLICATIONS 626 CITATIONS

SEE PROFILE

Asymptomatic Incisional Endometrioma Presenting as Abdominal Wall Mass: A case report

1. Al-Shraim MM, MBBS, FRCP (Canada), 2. Fikry A, MD, 3. Rahman GA, MBBS, FWACS, FICS,
4. AlShumrani G, MD, FRCR

1. Department of Pathology, 3. Surgery, 4. Radiology, College of Medicine, King Khalid University, Abha, Kingdom of Saudi Arabia.
2. Department of Surgery, Abha Private Hospital, Abha.

ABSTRACT

Asymptomatic incisional endometrioma of the anterior abdominal wall is rare. Clinical diagnosis may be difficult. We present a 26 year old woman with incisional abdominal wall endometrioma discovered 5 years after caesarian section. It was painless and there was no change in size with menstruation. The patient's body size was average with a palpable lump at the edge of the caesarian section scar. Clinically desmoid tumour was suspected. The patient underwent surgical excision. Histopathology confirmed endometrioma. There was no recurrence on three months follow-up.

KEY WORDS: endometriosis, endometrioma, abdominal wall, asymptomatic, caesarian scar.

Date Accepted for Publication: 25 January, 2012
NigerJMed 2012: 108-110
Copyright © 2012. Nigerian Journal of Medicine.

INTRODUCTION

When endometrial glands and stroma are found outside the endometrial cavity and uterine musculature, it is known as endometriosis. Though it can occur anywhere in the body, it is usually located in the pelvis. Endometrioma is a well defined form of endometriosis. Endometriosis is found in 15% of menstruating women. Localization to the anterior abdominal wall is rare³. It is found mainly in a scarred abdomen; though involving different previous procedures but mostly after caesarian section. Rarely it's found in patients without any history of surgery.⁵

This paper is aimed at reporting a rare case of asymptomatic abdominal wall endometrioma found in an incisional scar after 5 years of previous caesarian section.

CASE REPORT

We present a 26-year old female divorced patient who presented with a year history of painless slowly growing swelling in the anterior abdominal wall in the left groin at the site of previous caesarian section. There was no gastrointestinal or urinary symptom. Her menstrual cycles were regular and no change in the size of the abdominal wall mass in relation to menstruation.

Patient had her menarche at 15 years. She was para 1+0 1 alive. She had an emergency caesarian section for breech presentation 5 years earlier.

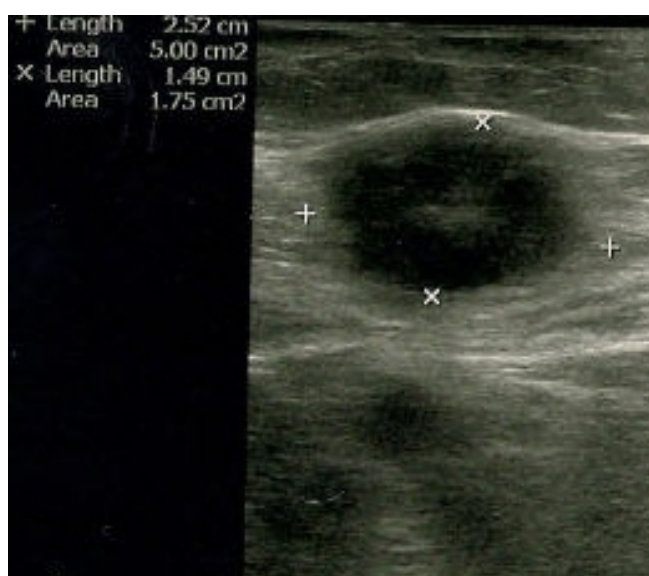On examination, the patient was not febrile, pale, jaundiced or cyanosed. The patient was of average body built and well oriented in place, person and time.

Abdominal examination revealed a left groin swelling at the lateral end of the previous caesarian section scar (Pfannestiel incision). It was a well defined mass about 2 x 2cm in size, firm in consistency, not tender and not warm. Tensing the abdominal wall muscle made the anterior abdominal wall mass more prominent. Further examination of the abdomen was normal. Rectal and vaginal examination was normal.

All other systems were essentially normal. A clinical diagnosis of desmoid tumour was made with subcutaneous lipoma as differential diagnosis. Complete blood count showed: Hb 11.2g/dl; WBC 4.6 x 10³ uL; platlets 241 x 10³/ Ul.

Ultrasound of the anterior abdominal wall (figure 1) was performed and showed a predominately hypoechoic intramuscular lesion measures 2.5x1.5 cm in the left lower quadrant underneath the left end of the surgical scar. Internal echoes were noted in this lesion. The inner margins of the lesion showed some irregularity. However, there was no speculation or invasion through

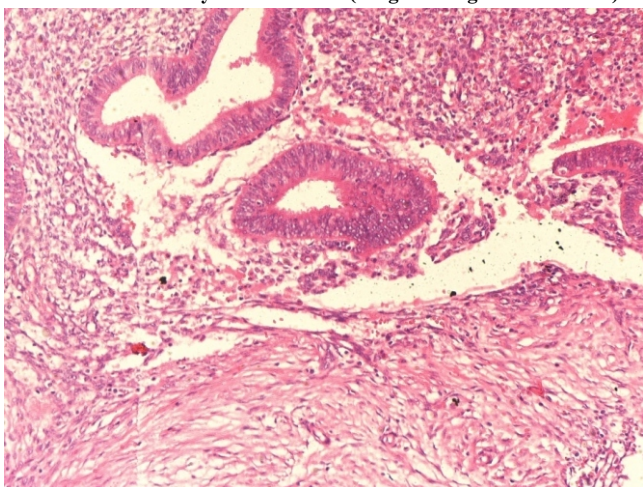
Fig 1: Grey-scale ultrasound image of the anterior abdominal wall showed the hypoechoic intramuscular lesion



the soft tissue planes. Considering the clinical diagnosis of desmoid tumor, it was entertained as a possibility by ultrasound.

The anterior abdominal wall mass was excised with clear margin including part of the anterior rectus sheath. Postoperative course was uneventful. On histopathology, microscopic examination showed presence of endometrial glands and stroma, surrounded by fibrous tissue (Figure 2). The endometrial stroma has occasional hemosiderin-laden macrophages. There was no hyperplasia, metaplasia or malignancy. The margins were free of endometrial tissue histologically. Three months of follow-up showed no recurrence.

Fig 2: Photomicrograph (H&E): showing endometrial glands and stroma surrounded by fibrous tissue. (Original magnification x400)



DISCUSSION

Incisional abdominal wall endometrioma is commonly associated with previous scars. It is associated with a caesarian section scar in 57% and hysterectomy in 11% of cases.⁶ It constitutes about 4% of endometriosis and 0.2 to 0.8% of patients with previous caesarian section.^{4,7} The age of the patient was 26 years old which is within the reported average figure of 20-34 years in the literature.⁸

Though the pathogenesis of endometriosis is not clear, there are several proposed theories. The three main theories are: implantation theory, the direct transplantation and the coelomic metaplasia theory.⁹ Local endometrial cell transplant seems to be the most probable pathophysiological mechanism in anterior abdominal wall endometrioma.⁹

The patient was seen 5 years after previous caesarian section. The average interval between previous surgery and presentation with endometrioma is 1.9 to 7 years^{7,8,9} though an isolated case of 15 years after previous surgery was reported in the literature.¹⁰

The size of anterior abdominal wall endometrioma varies. The patient presented had a 2.5cm mass, which is within the reported size in the literature of 1-12 cm in the literature.¹

The patient had a single lump though it can be multiple. The diagnosis can be difficult because there is no specific finding, however in symptomatic patients, presence of pain and change in size during menses can be helpful. The differential diagnoses include abscess, granuloma, hernia, haematoma, subcutaneous lipoma and tumours (desmoids tumour, sarcoma, lymphoma, melanoma).

As a result of difficulty in clinical diagnosis; ultrasound scan, Doppler, computed tomography (CT), and magnetic resonance imaging (MRI) have been found to be useful imaging techniques. The ultrasound findings in this patient showed hypoechoic lesion with internal echoes. Sometimes the lesion may be vascular, solid with or without cystic changes.⁴ MRI performs better than CT for identifying hemorrhage and soft tissue plane.¹

There is usually difficulty in distinguishing abdominal wall endometrioma from other surgical conditions. Fine needle aspiration (FNA) may confirm the diagnosis.⁷ This may sometimes be ultrasound-guided especially when the lump is very small. Fine needle aspiration usually yields chocolate-coloured fluid, though is contraindicated if hernia is a possibility.¹

Surgical excision is the only effective treatment and a wide clear margin is the key point to prevent recurrence. The patient in this report benefitted from excision with clear margin though part of the anterior rectus sheath had to be excised to achieve this. There was no recurrence. Surgical excision as in this case was both diagnostic and therapeutic.

Of importance in the management of patients with abdominal wall endometrioma is the prevention of malignant transformation and recurrence after excision. Recurrence is closely related to the size and depth of the lesion. About 4% recurrence rate has been reported.¹

Some authors have suggested that at the end of caesarian section and before closure of wound, the abdominal wall incision should be thoroughly cleaned and generously irrigated with high-jet saline solution to prevent abdominal wall endometrioma.

In patients with previous gynaecological procedures presenting with a mass close to a previous scar, endometrioma should be considered as a rare differential diagnosis. The pathologists can also help with information about the margin in predicting recurrence.

We've presented a 26 year old woman with abdominal wall endometrioma who was asymptomatic and benefited from surgical excision without recurrence.

Competing Interest

No competing interest

Author's Contributions

All the authors contributed to the concept of the manuscript, reviewed the literature, wrote and reviewed the manuscript; M. Al-Shraim and G. Alshumrani evaluated the histopathology and radiology reports, respectively.

REFERENCES

1. Robert S Schenken, Pathogenesis, clinical features and diagnosis of endometrioma. Uptodate. July 15, 2010.
2. Merran S., Karila-Cohen P., Incisional cutaneous endometrioma of the abdominal wall: report of two cases, *J Radiol*, 2004, 85:409-410.
3. Erkan N., Hacıyanlı M., Sayhan H., Abdominal all endometriomas, *Int J Gynaecol Obstet*, 2005, 89:59-60.
4. Hensen J. H., Van Breda Vriesman A. C., Puylaert J. B. Abdominal wall endometriosis: clinical presentation and imaging features with emphasis on sonography, *AJR Am J Roentgenol*, 2006, 186:616-620.
5. Kaunitz A., Di Sant Agnese P. A., Needle tract endometriosis: an unusual complication of amniocentesis, *Obstet Gynecol*, 1979, 54:753-755.
6. Horton JD, Dezee KJ, Ahnfeldt EP, Wagner M. Abdominal wall endometriosis: a surgeon's perspective and review of 445 cases. *Am J Surg* 2008; 196:207.
7. Blanco RG., Parithivel VS., Shah AK. *et al.*, Abdominal wall endometriomas, *Am J Surg*, 2003, 185:596-598.
8. Wasfie T., Gomez E., Seon S., Zado B., Abdominal wall endometrioma after cesarean section: a preventable complication, *Int Surg*, 2002, 87:175-177.
9. Picod G., Boulanger L., Bounoua F. et al., Endométriose pariétale sur cicatrice de césarienne: à propos de 15 cas, *Gynécol Obstét Fertilité*, 2006, 34:813.
10. Tica VI, Tomescu CL, Tomescu A, Micu L, Zaher M, Bafani S, Beghim M, Serbanescu L, Tica I. Asymptomatic abdominal wall endometrioma 15 years after cesarian section. *Romanian Journal of Morphology and Embryology* 2006; 47(3): 301-304.