



Pelagia Research Library

European Journal of Experimental Biology, 2014, 4(6):32-39



Anti-uveitogenic effect of Xylopic acid in Sprague-Dawley rats

Samuel Kyei^{1*}, Elvis Ofori Ameyaw², George Asumeng Koffuor³, Johnson Nyarko Boampong², Eric Woode³, Blessing Barilee Abueh¹, Owusu-Afriyie Osei⁴ and Akua Afriyie Karikari²

¹Department of Optometry, School of Physical Sciences, University of Cape Coast, Cape Coast, Ghana

²Department of Biomedical and Forensic Sciences, School of Biological Sciences, University of Cape Coast, Cape Coast, Ghana

³Department of Pharmacology, Faculty of Pharmacy and Pharmaceutical Sciences, Kwame Nkrumah University of Science and Technology, Kumasi, Ghana

⁴Department of Pathology, Komfo Anokye Teaching Hospital, Kumasi, Ghana

ABSTRACT

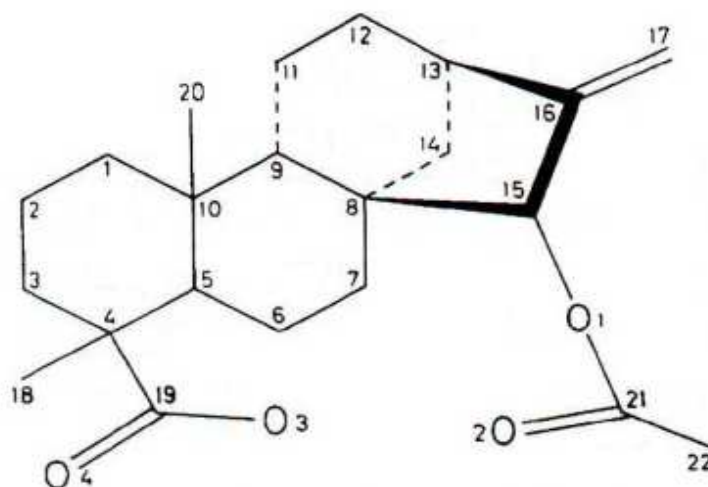
Uveitis, intraocular inflammatory disorder is one of the leading causes of blindness in the world. This study investigated the curative effect of xylopic acid on endotoxin-induced uveitis in Sprague-Dawley rats. Uveitis was induced in rats by injecting 110 µg lipopolysaccharide (LPS) subcutaneously. Clinical signs of uveitis were assessed with a slit lamp. Polymorphonuclear neutrophils and total proteins in the aqueous humour of the eyes were estimated and these markers of inflammation were elevated in the control groups. Histopathological assessments of inflammation in the ocular tissues were also performed. There were significant reductions ($P \leq 0.05$) in vasodilatation of iris vessels, exudation, polymorphonuclear neutrophils and total proteins in the aqueous humour of xylopic acid and prednisolone treated uveitic rats compare to the untreated (control). Histopathological assessments revealed resolution of uveitis in treatment groups but not the untreated. This shows that oral administration of xylopic acid has ocular anti-inflammatory effect in Sprague-Dawley rats.

Keywords: Uveitis, Lipopolysaccharide, Anti-Inflammatory, Xylopic acid, *Xylopic acid*

INTRODUCTION

Uveitis is an intraocular inflammation of the eye; it involves the uvea [1]. It is one of the leading causes of blindness in the world [2]. A recent study found that the extrapolated 10-year incidence of uveitis was almost three times higher than that reported almost 40 years previously [3]. Most uveitis patients present at an age where they are in the most active period of their working life. The age distribution makes uveitis a group of ocular diseases with an important socioeconomic consequence. Approximately 5-20% of legal blindness in developed countries is due to uveitis [3]. Uveitis affects roughly 1 in 4500 people and is most common between the ages 20 to 60, with men and women affected equally. In the west, anterior uveitis accounts for 50% - 90% of uveitis cases while in Asian countries the proportion drops to about 28% and 50% [4]. Therapy is usually aimed at suppressing the immune response with corticosteroids as the first line treatment. Steroidal anti-inflammatory drugs, which are the mainstream treatment for uveitis, are associated with severe adverse effect such as cataract, increased intraocular pressure, delayed wound healing, fluid retention, mood changes (depression or euphoria), diabetes, hypertension,

osteoporosis, nausea, increased appetite, and weight gain [5-7]. Without aggressive treatment, the severe types of uveitis often lead to visual loss. The usual systemic treatment of continually suppressing a patient's entire immune system by using corticosteroids, sometimes along with other anti-inflammatory medications, appears effective. However, some eye care professionals are concerned that such treatment may lead to complications, which may require surgical correction [8]. Therefore, the need for alternative drugs with minimal adverse effects is urgently desirable. Xylopic acid (XA) is a diterpenoid found in the fruits of *Xylopic aethiopica* [9]. The fruits of *Xylopic aethiopica* are used to treat inflammatory diseases such as arthritis, asthma and rheumatism in Ghana. Furthermore, ethanolic extract of the fruits have demonstrated anti-inflammatory properties *in vivo* [10]. Xylopic acid has also demonstrated activities against some of the inflammatory mediators such as prostaglandin E₂ and macrophages but its effect in ocular inflammation has not been demonstrated [11,12]. It is for this reason that this study sought to evaluate the ocular anti-inflammatory effect of xylopic acid on endotoxin-induced uveitis in Sprague-Dawley rats. The structure of xylopic acid [15 β -acetoxy-(-)-kaur-16-en-19-oic acid] is depicted in figure 1 below:



MATERIALS AND METHODS

Obtaining Xylopic acid (15 β -Acetoxy-(-)-kaur-16-en-19-oic Acid)

Xylopic acid was obtained for this study by extraction from the dried fruits of *Xylopic aethiopica*. The dried fruits were collected from the Botanical Gardens (06°41'6.39"N; 01°33'45.35"W) of Kwame Nkrumah University of Science and Technology (KNUST), Kumasi, Ghana, and authenticated at the Department of Pharmacognosy, Faculty of Pharmacy and Pharmaceutical Sciences, College of Health Sciences, KNUST (voucher specimen No. FP/09/77). The isolation and purification of xylopic acid was done as described elsewhere [11]. Briefly, 0.36 kg of the pulverised fruit was extracted with 5 L of petroleum ether (40-60 °C). Crude xylopic acid crystals formed after the concentrate had stood for a couple of days were washed with petroleum ether (40-60 °C) and purified by recrystallisation using ethanol [percentage yield of 1.41 % (w/w)]. The purity of the isolated xylopic acid as determined by HPLC was 95%.

Drugs and chemicals used

Lipopolysaccharide (LPS) and endotoxin from *Escherichia coli* (Calbiochem, EMD Chemicals, San Diego, CA, USA) was used to induce uveitis. Bicinchoninic Acid (BCA) protein assay reagent kit (Pierce, Rockford, IL, USA) was used to determine total protein in aqueous humour. Prednisolone (Letap Pharmaceuticals Ltd., Accra, Ghana) was the reference anti-inflammatory agent in this study. Chloroform was used to euthanize the animals and Normal saline solution (Claris lifesciences limited, Chacharwadi, India) was the vehicle in which other drugs were dissolved in.

Ethical and Biosafety Considerations

Institutional research clearance was obtained before the study was undertaken. Laboratory study was carried out in a level 2 biosafety laboratory. Protocols for the study were approved by the Department of Pharmacology, KNUST

Ethics Committee. All activities during the studies conformed to accepted principles for laboratory animal use and care (EU directive of 1986: 86/609/EEC). All the technical team observed all institutional biosafety guidelines for protection of personnel and laboratory. All procedures and techniques used in this study were in accordance with the Association for research into vision and Ophthalmology (ARVO).

Animals and Husbandry

A total of 36, 6-8 weeks old Sprague-Dawley rats (100-150g) purchased from the Centre for Scientific Research into Plant Medicine (Mampong-Akwapim, Ghana) were maintained in the Animal Laboratory of the School of Biological Sciences of the University of Cape Coast, Ghana. The animals were housed in polyacrylic cages (34cm x 47cm x 18cm) with soft wood shaving as bedding, under ambient laboratory conditions and fed with normal commercial pellet diet (AGRICARE, Kumasi) and water *ad libitum*. Female rats were non-pregnant.

Dosing of Drugs

Doses of xylopic acid (XA) were selected based on preliminary experiments. The dose of prednisolone used was calculated from treatment doses for uveitis recorded in official compendia. Dosing was done once daily at a volume of 10 ml/kg body weight. Individual dose volumes were calculated based on the animal's most recent recorded body weight.

Endotoxin-induced Uveitis

Baseline body temperatures of Sprague-Dawley rats, taken from the rectum, were recorded using a digital thermometer (Clinical Guard, Atlanta, USA). Their eyes were assessed using slit lamp (Lombart Instrument Company, Norfolk, VA) fitted with a digital microscope camera (Olympus, Tokyo, Japan) and images of the anterior chamber captured. The rats were then injected LPS (110 ug; s.c) to induce uveitis. At 2 h after LPS inoculation, the body temperatures were again recorded. Rats that showed an increase in temperature of 0.2°C and more were selected and grouped into six groups (n=6). The groups were treated with 10, 30 or 100mg/kg of xylopic acid—groups 1-3, 30 mg/kg Prednisolone—group 4, or 10ml/kg normal saline —group 5. A “no treatment group (not inoculated LPS)” was also kept under experimental conditions—group 6. After 18h post-LPS inoculation, the eyes were assessed again for vasodilation and exudation (clinical signs of uveitis) using the slit lamp and photographs of the anterior chamber were again taken for clinical grading of uveitis. The clinical score of inflammation was determined from the photographs after which the animals were euthanized and the anterior chamber punctured with a 30 gauge needle, and the aqueous humor from both eyes collected (about 15-20ul/rat) into eppendorf tubes for estimation of the presence of PMNs and total proteins [13].

Clinical Grading of Uveitis

This was done as described by Yamashiro et al (2001[14]) as follows: Iris hyperemia (0-2), Flare (0-1), Cells in the anterior chamber (0-2), Hypopyon (0-1), Miosis (0-1). The maximum possible score was 7. The clinical score was computed as the mean of each group (n=6).

Polymorphonuclear Neutrophil Count

A 1:10 dilution with Turk solution of the aqueous humour from rats treated with 10, 30, and 100 mg/kg of xylopic acid, 30 mg/kg prednisolone, 10 ml/kg normal saline, as well as from normal rats without LPS challenge, were introduced onto the counting chamber of the Improved Neubauer Haemocytometer (Depth 0.1mm, Area: 1/400 mm²; Yancheng Cordial Lab Glassware Co. Ltd, Jiangsu, China (Mainland). Polymorphonuclear neutrophils were counted from the four large squares (volume: 0.4 mm³) of the counting area using Ceti magnum-T/trinocular microscope for fluorescence (Medline Scientific limited, UK) under objective magnification of 40x. The number of PMNs was determined per mm³ of aqueous humour (taking into consideration the dilution factor).

Estimation of Total Protein Concentration

BCA protein assay kit was used to estimate total protein concentration in the aqueous humour obtained from the enucleated rat eyes. The protein concentration was determined by pipetting 10 µl of aqueous humour from; LPS inoculated rats treated with 10, 30, and 100 mg/kg of xylopic acid, 30 mg/kg prednisolone, 10 ml/kg normal saline, normal rats without LPS challenge, and standard bovine serum albumin (BSA), into a 96-well microplate. A 200 µl volume of working reagent, constituted according to the manufacturer's instructions, was mixed thoroughly with the content of each well and shaken for 30 seconds. It was then incubated at 37°C for 30 minutes and allowed to cool to room temperature. Absorbances of the mixtures were measured at 562 nm using an ELx800 absorbance microplate reader (BioTek Instruments, Inc., USA). Each determination was in triplicate.

Histopathological Assessment

The enucleated eyes of the animals were fixed in 4% phosphate-buffered paraformaldehyde, and embedded in paraffin. Sections of normal, uveitic, and uveitic but treated (Xylopic acid, and Prednisolone) rats were made and stained with hematoxylin and eosin (Yamashiro *et al.*, 2001[14]) and fixed on glass slides for microscopic examination at the Pathology Department of the Komfo Anokye Teaching Hospital, Kumasi, Ghana for histopathological assessment by a Specialist Pathologist.

Data Analysis

Bar graphs were obtained by the software GraphPad Prism for Windows version 5 (GraphPad Software, San Diego, CA, USA) and were subjected to One-Way Analysis of Variance (ANOVA) with Dunnet's *post hoc* test. $P \leq 0.05$ was considered statistically significant in all analysis.

RESULTS***Clinical Score of Ocular Inflammation***

Clinical scores of ocular inflammation were graded based on slit lamp assessment of the anterior chamber. The ocular inflammatory parameters assessed were iris hyperemia, flares and cells in the anterior chamber, hypopyon and miosis with a maximum possible score of 7 for each rat. Photographs of the anterior chamber were taken. The uveitic control group showed significantly higher degree of ocular inflammation as compared to the prednisolone and xylopic acid treated groups (Figure 2, 3). This was seen as significant reduction in vasodilation of the iris vessels, miosis and exudation into the anterior chamber relative to the uveitic control; seen as significant decrements ($P \leq 0.05$) in clinical scores of inflammation.

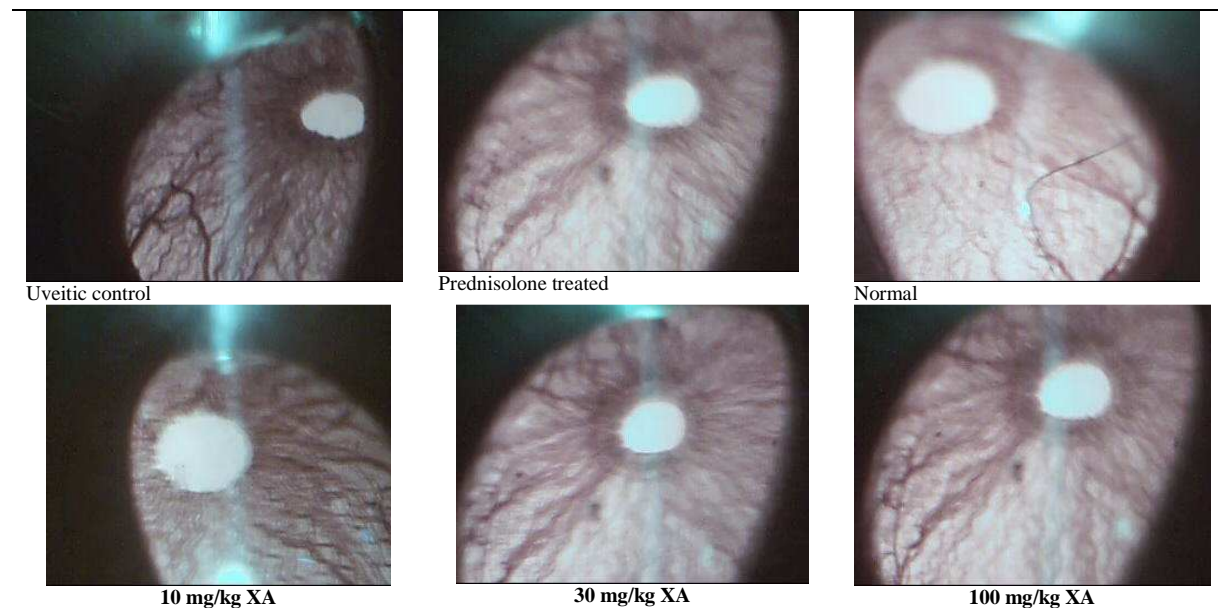


Figure 2: Slit lamp biomicroscope camera photographs obtained for normal, uveitic, and uveitic but treated eyes using various doses of xylopic acid, and prednisolone

Polymorphonuclear Neutrophil (PMN) Count

There were significant reductions ($P \leq 0.001$) in PMNs in the prednisolone treated and xylopic acid-treated groups compared to the uveitic control group (Figure 4). The normal control (without LPS challenge) group showed significantly ($P \leq 0.001$) low numbers of cell infiltration.

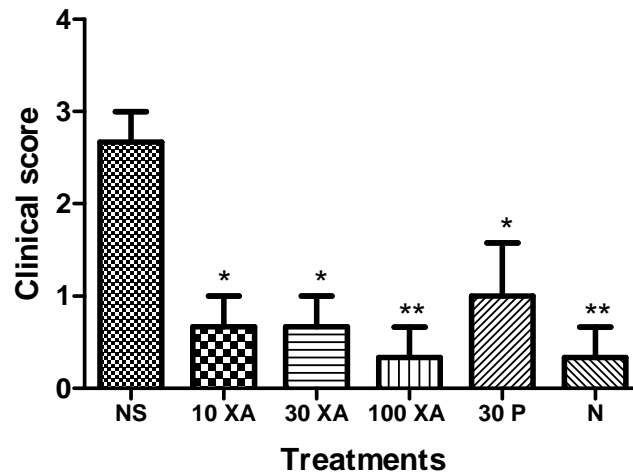


Figure 3: The clinical score of inflammation for 10, 30 and 100 mg/kg xylopic acid (XA) and 30 mg/kg prednisolone (P), and 10 ml/kg normal saline (NS) in endotoxin-induced uveitis. N represents normal animals kept under the same experimental conditions. Significant difference between various groups and NS-treated was established using One-Way Analysis of Variance (ANOVA) followed by Dunnet's post hoc test. * $P \leq 0.05$; ** $P \leq 0.01$ (n=6)

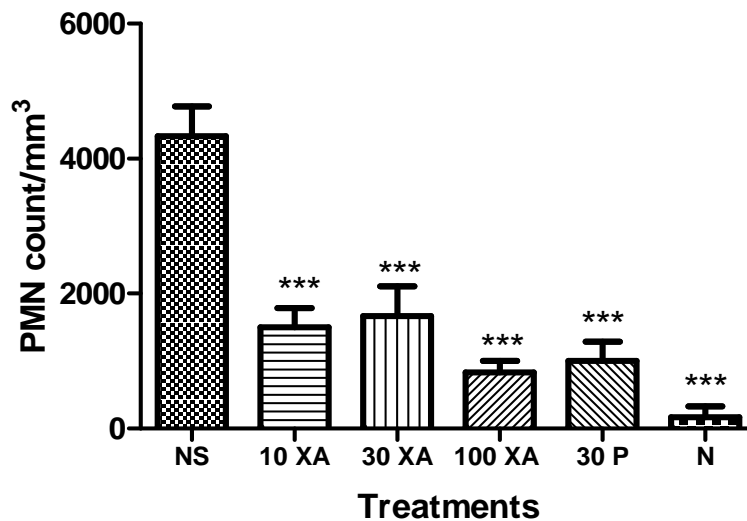


Figure 4: The effect of 10, 30 and 100 mg/kg xylopic acid (XA) and 30 mg/kg prednisolone (P), and 10 ml/kg normal saline (NS) on PMN count in the anterior chamber of the eyes of endotoxin-induced uveitic rats. Significant difference between various groups and the NS-treated was established using One-Way Analysis of Variance (ANOVA) followed by Dunnet's post hoc test. *** $P \leq 0.001$ (n=6)

Total Protein Concentration

Total protein concentration was significantly low ($P \leq 0.001$) in Prednisolone-treated as well as the xylopic acid-treated uveitic rats, and the normal control compared to uveitic rats treated with normal saline (Figure 5).

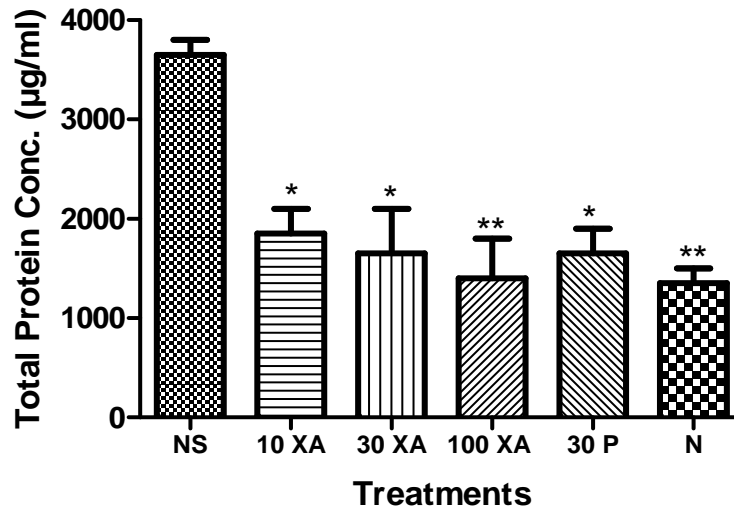


Figure 5: The effect of 10, 30 and 100 mg/kg xylopic acid (XA) and 30 mg/kg prednisolone (P), and 10 ml/kg normal saline (NS) on total protein concentration in the aqueous humour of the eyes of endotoxin-induced uveitic rats. Significant difference between various groups and the NS-treated was established using One-Way Analysis of Variance (ANOVA) followed by Dunnet’s post hoc test. *P<0.05; **P ≤ 0.01 (n=6)

Histopathological Assessment

The histopatological assessment did not show any remarkable signs of inflammation in anterior uvea in all rats treated with Prednisolone, xylopic acid-treated uveitic rats, and the normal control. However, there were histopathological signs of inflammation characterized by neutrophil infiltration into the uveal tissues (Figure 6).

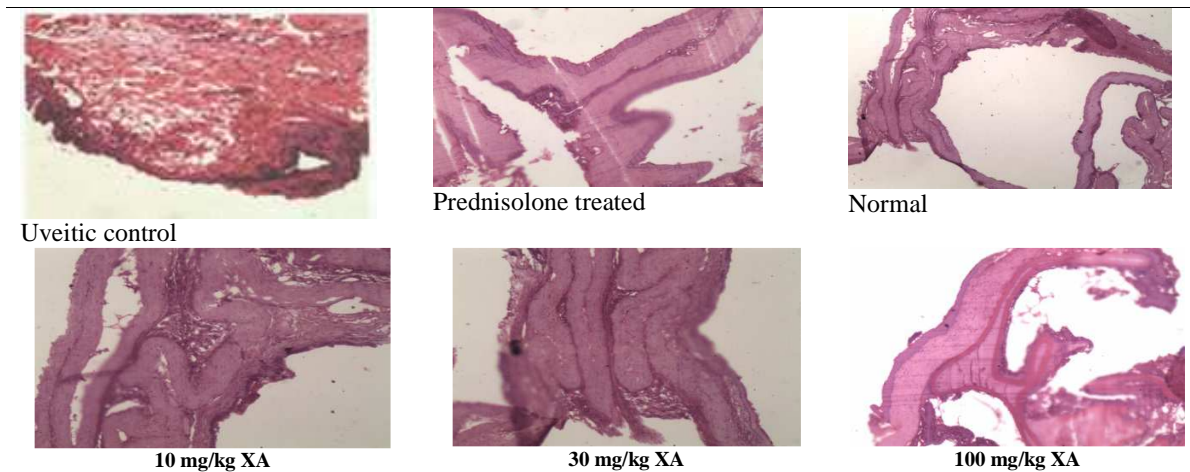


Figure 6: Photomicrographs taken from the study showing no inflammatory condition (normal control), uveitis, and uveitic but treated with prednisolone or xylopic acid in the eyes of Sprague-Dawley rats

DISCUSSION

Xylopic acid administered at three dose levels exerted dose-dependent curative ocular anti-inflammatory properties in the rat model of LPS-induced uveitis. Endotoxin induced uveitis (EIU) caused by LPS is an animal model of acute intraocular inflammation that mimics human anterior uveitis [14]. LPS, a glycolipid from the outer cell membranes of Gram-negative bacteria is a pro-inflammatory component and is used to induce uveitis in animals by

systemic or ocular route [15]. LPS-induced uveitis in the rat provides a simple, reproducible model for ocular inflammation without requiring direct eye manipulation [16]. Pyrexia, infiltration of inflammatory cells, vasodilatation of the iris vessels, miosis, hypopyon, protein exudation and flare are classical signs of uveitis caused by LPS subcutaneous challenge. These symptoms come to play as a result of activation of macrophages by interferon secreted by infiltrating lymphocytes. The macrophages together with neutrophils under the influence of cytokines produce PGE₂ and NO. This finally results in breakdown of the blood-aqueous barrier causing uveitis [17].

A putative drug for the treatment of uveitis therefore is one that will reduce vasodilatation, hypopyon, protein exudates, and flares and indirectly result in the lowering of PMNs in the inflamed tissue. Xylopic acid showed all these characteristics in this study indicating that it is a good candidate for the treatment of this condition.

The inhibition of the vasodilatation of the iris vessels and flare by xylopic could have been due to the blocking of further production of PGE₂ (as a result of inhibition of neutrophils and activated macrophages) and/or the inhibition of the effect of the already produced and released PGE₂ on the blood vessels. Indeed, xylopic acid and aqueous extract of *Xylopic aethiopia* have been shown to inhibit pro-inflammatory mediators such as PGE₂ and macrophages [10, 11].

Adhesion molecules such as β_2 -integrin and intercellular adhesion molecule-1 (ICAM-1) play critical roles in promoting neutrophil infiltration in EIU [18]. XA may have prevented the leucocyte infiltration by suppressing these molecules.

Total protein in the aqueous humour associated with LPS-induced uveitis was significantly reduced by XA. It is generally accepted that the breakdown of the blood-aqueous barrier in uveitis results in cellular infiltration and an increase in protein permeability. It has also been demonstrated that these two phenomena do not always occur in tandem. While the cellular infiltration into the aqueous humour is significantly mediated by P-selectin, it is not so for protein infiltration into the aqueous humour [12]. Furthermore, E-selectin significantly mediates cellular infiltration into aqueous humour but not protein infiltration [19]. Protein infiltration is however blocked by combined inhibition of P- and E-selectins [20]. This implies that XA may act non-selectively on P- and E-selectins to produce its anti-ocular inflammatory properties. This is explained by the fact that, the non-selective selectin ligand, α -Sialyl Lewis X oligosaccharide (SLeX-OS) significantly blocks protein infiltration. Cytokines like IL-10, TGF- β 2 and even IL-12 as well as IL-1RA and FasL-induced apoptosis may be involved in the disease resolution [21] and xylopic acid may have promoted the expression of these anti-inflammatory cytokines.

CONCLUSION

Oral administration of xylopic acid has curative effect on endotoxin-induced uveitis in Sprague Dawley rats.

Acknowledgements

The Authors are grateful to Dr Carl Halladay Abraham of the Department of Optometry, University of Cape Coast for assisting in the clinical assessment of uveitis in the rats' eyes.

REFERENCES

- [1] Gritz DC, Wong IG, *Ophthalmol*, **2004**, 111,491.
- [2] Nussenblatt RB, *Int Ophthalmol*, **1990**,14, 303.
- [3] Murry P, What is uveitis? *International Uveitis Study Group (IUSG)*. Available from: [http://www.iusg.net/page7/What is Uveitis.html](http://www.iusg.net/page7/What%20is%20Uveitis.html). Last accessed on 2012 October 20th.
- [4] Forrester JV, Xu H, Kuffová L, Dick AD, McMenamin PG, *Immunol Rev*, **2010**, 234, 282.
- [5] Beutler B, Milsark IW, Cerami AC, *Science*, **1985**, 229,869.
- [6] Lehmann V, Freudenberg MA, Galanos C, *J Exp Med*, **1987**,165.
- [7] Fisher DA, *West J Med*, 1995, 162,123.
- [8] Clark AF, Wordinger RJ, *Exp Eye Res*, **2009**, 88,403.
- [9] Burkill HM, *The useful plants of west tropical Africa*. 2nd Edition, vol 1, Families A-D, Royal Botanic Gardens. Kew (K): Richmond, United Kingdom, **1985**

-
- [10] Obiri DD, Osafo N, *J Ethnopharmacol.*, **2013**, 148, 940.
- [11] Woode E, Ameyaw EO, Ainooson GK, Abotsi WKM, Boakye-Gyasi E, Oppong- Kyekyeku J, *Pharmacologia.*, **2013**, 4, 285.
- [12] Boampong JN, Ameyaw EO, Aboagye B, Asare K, Kyei S, Donfack JH, Woode E, *Journal of Parasitology Research.*, **2013**.
- [13] Kyei S, Koffour GA, Boampong JN, Owusu-Afriyie O, *J Nat Pharm*, **2012**, 3,99.
- [14] Yamashiro K, Kiryu J, Tsujikawa A, Honjo M, Nonaka A, Miyamoto K, Honda Y, Tanihara H, Ogura Y, *Invest Ophthalmol Vis Sci.*, **2001**, 7,1553.
- [15] Rosenbaum JT, Mc Devitt HO, Guss RB, Egbert PR, *Nature*, **1980**, 286,611.
- [16] Li Q, Peng B, Whitcup SM, Jang SU, Chan CC, *Exp Eye Res*, **1995**, 61,629.
- [17] Cousins SW, Guss RB, Howes EL, Jr Rosenbaum JT, *Exp Eye Res*, **1984**, 39,665.
- [18] Medeiros PR, Rodrigues GB, Figueiredo CP, Jr., Grumman A, Jr., Menezes-de-Lima O, Passos GF, Calixto JB, *Mol Pharmacol*, **2008**, 74,154
- [19] Suzuma K, Mandai M, Kogishi J, Tojo SJ, Honda Y, Yoshimura N, *Invet Ophthamol Vis Sci*, **1997**, 38,1610.
- [20] Suzuma I, Mandai M, Suzuma K, Ishida K, Tojo SJ, Honda Y, *Invet Ophthamol Vis Sci*, **1998**, 39,1620.
- [21] Mc Menamin G, *Eye*, **1997**, 11, 183.